

13 – Skin and Soft Tissue Infections

Speaker: Helen Boucher, MD

IDBR
INFECTIOUS DISEASE BOARD REVIEW
AUGUST 20-24
2022

Skin and Soft Tissue Infection

Helen W. Boucher, MD, FACP, FIDSA
Dean ad interim
Professor of Medicine
Tufts University School of Medicine
Chief Academic Officer, Tufts Medicine

7/18/2022

IDBR
INFECTIOUS DISEASE BOARD REVIEW
AUGUST 20-24
2022

Disclosures of Financial Relationships with Relevant Commercial Interests

- Editor
 - ID Clinics of North America
 - Antimicrobial Agents and Chemotherapy
 - Sanford Guide
- Voting Member, Presidential Advisory Council on Combating Antibiotic Resistant Bacteria (PACCARB)

Question #1

A 25 year old female suffers a cat bite on the forearm. She presents one hour later for care. If no antibacterial is administered, the percentage of such patients that get infected is:

- A. 0-10 %
- B. 10-30 %
- C. 30-70 %
- D. 70-100 %

3

Management of Animal Bites

- Wound care: irrigation, debridement
- Image for fracture or as baseline for osteo or to detect foreign body ?
- Wound closure: NO
- Anticipatory (prophylactic) antibiotics
- Vaccines (tetanus and rabies)

4

Cat Bites

- 30-50% cat bites become infected with bacteria
- Wound types: puncture
- Microbiology: 63% polymicrobial
- Infection type:
 - Nonpurulent wound with cellulitis, lymphangitis, or both (42%)
 - Purulent wound without abscess (39%)
 - Abscesses (19%)

Organism	Percentage
Aerobic organisms	
Pasteurella	75
Streptococcus	46
Staphylococcus	35
Neisseria *	35
Moraxella	35
Corynebacterium	28
Enterococcus	12
Bacillus	11
Anaerobic organisms	
Fusobacterium	33
Porphyromonas	30
Bacteroides	28

Abrahamian FM1, Goldstein EJ. Microbiology of animal bite wound infections. Clin Microbiol Rev. 2011 Apr;24(2):231-46. doi: 10.1128/CMR.00041-10. NEJM 1999; 340: 85-92

5

Pasteurella multocida

- In saliva of > 90% of cats and over 80% of wounds get infected
- Different species, *Pasteurella canis*, in saliva of 50% of dogs and only 2-10% get infected
- Small aerobic Gram-Negative bacillus
- Hard to remember antibiotic susceptibility profile, but amoxicillin sensitive; alternatives can be tricky

6

13 – Skin and Soft Tissue Infections

Speaker: Helen Boucher, MD

Six Pathogens That Can Cause Infection After Cat Bites

1. *Pasteurella species*
2. Anaerobic bacteria: e.g., *Fusobacteria*
3. *Bartonella henselae* (Cat Scratch disease)
4. Rabies virus
5. *S. aureus*
6. *Streptococcal species*

7

Question #2

INFECTION DISEASE BOARD REVIEW 2022 PREVIEW QUESTION

A 50 year old female with alcohol substance abuse disorder suffered a provoked dog bite

- Bite was cleansed, tetanus toxoid given, and the dog placed under observation
- Patient is post-elective splenectomy for ITP; she received pneumococcal vaccine one year ago
- One day later, the patient is admitted to the ICU in septic shock with severe DIC and peripheral symmetric gangrene of the tips of her fingers/toes

8

Question #2

INFECTION DISEASE BOARD REVIEW 2022 PREVIEW QUESTION

Which one of the following is the most likely etiologic bacteria?

- A. *Pasteurella canis*
- B. *Capnocytophaga canimorsus*
- C. *Fusobacterium sp.*
- D. *Bartonella henselae*

9

Dog Bites and Splenectomy

- Only 2-10 % of dog bites get infected
- Potential pathogens from
 - Dog's mouth:
 - *Pasteurella canis*, *Capnocytophaga canimorsus*
 - Human skin: *S. aureus*, *S. pyogenes*
- *Capnocytophaga* is an important cause of overwhelming sepsis in splenectomized patients
- *Capnocytophaga*
 - Susceptible to: AM/CL, PIP/Tazo, Penicillin G, and clindamycin
 - Resistant to: TMP/SMX and maybe vancomycin

10

Question #3

A 45 year old USA male experiencing homelessness presents with fever and severe polymyalgia. On physical exam, animal bite marks found around his left ankle. A faint rash is visible on his extremities. Within 24 hours, blood cultures are positive for pleomorphic gram-negative bacilli.

Which one of the following is the most likely diagnosis?

- A. *Pasteurella multocida*?
- B. *Haemophilus parainfluenza*?
- C. *Spirillum minus*?
- D. *Streptobacillus moniliformis*?

11

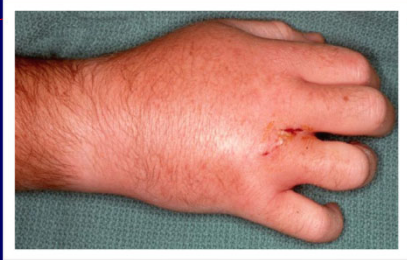Rat bite fever

- USA: *Streptobacillus moniliformis*
- Asia: *Spirillum minus*
- Bites or contaminated food/water
- *S. moniliformis*:
 - Fever, extremity rash
 - Macular/papular, pustular, petechial, purpuric
 - Symmetrical polyarthralgia
- Treatment: Penicillin or doxycycline

12

13 – Skin and Soft Tissue Infections

Speaker: Helen Boucher, MD



13

Question #4

infectious disease board review 2022 PREVIEW QUESTION

A 35 year old male suffers a clenched fist injury in a barroom brawl. He presents 18 hours later with fever and a tender, red, warm fist wound. Gram stain of bloody exudate shows a small gram-negative rod with some coccobacillary forms. The aerobic culture is positive for viridans streptococci*

Which one of the following organisms is the likely etiologic agent?

- A. *Viridans streptococci*?
- B. *Eikenella corrodens*?
- C. *Peptostreptococcus*?
- D. *Fusobacterium* species?

*Talan, D. CID 2003; 37: 1481

14

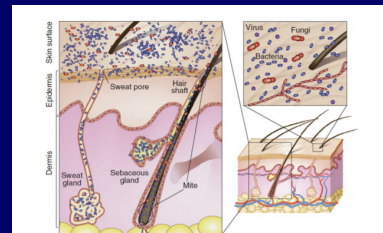
Question #5 (Extra Credit)

Medicinal leeches are applied to a non-healing leg ulcer. Which one of the following pathogens is found in the “mouth” of the leech ?

- A. *Alcaligenes xylosoxidans*
- B. *Aeromonas hydrophila*
- C. *Acinetobacter baumannii*
- D. *Arcanobacterium haemolyticum*

15

The Skin: Local Invasion by Structure



[https://www.id.theclinics.com/article/S0891-5520\(20\)30090-8/pdf](https://www.id.theclinics.com/article/S0891-5520(20)30090-8/pdf)

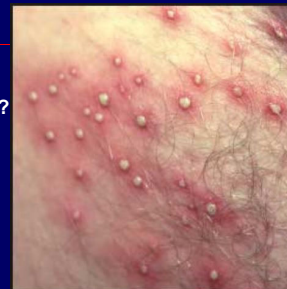16

Skin Infections: Predisposing Factors

- Trauma to normal skin
- Immune deficiency
- Disrupted venous or lymphatic drainage
- Local inflammatory disorder
- Presence of foreign body
- Vascular insufficiency
- Obesity; poor hygiene

17

What is this?



18

13 – Skin and Soft Tissue Infections

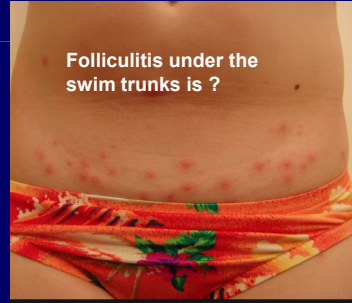Speaker: Helen Boucher, MD

Superficial Folliculitis

- Purulence (sometimes mixed with blood) where hair follicles exit skin
- Etiology:
 1. *S. aureus*
 2. *P. aeruginosa* (hot tub)
 3. *C. albicans* (esp. in obese patient)
 4. *Malassezia furfur* - lipophilic yeast (former *Pityrosporum* sp)
 5. Idiopathic eosinophilic pustular folliculitis in AIDS patients

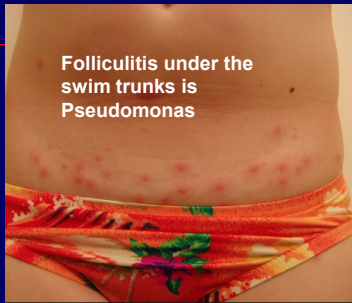19

Folliculitis under the swim trunks is ?



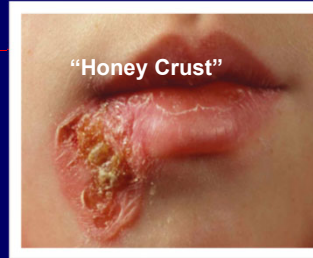20

Folliculitis under the swim trunks is *Pseudomonas*



21

“Honey Crust”



Microbial Etiology?

22

Streptococcal Infection of the Epidermis Name of the Clinical Syndrome?

Infection of outer layers of epidermis with production of “honey-crust” scales
Prevalent in warm, humid environments – esp. in children.

Microbial etiology

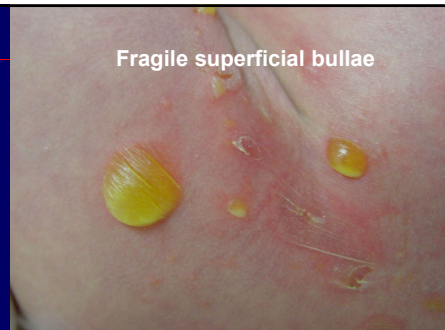
- Streptococci: Groups A, B, C, G

Name?

- **Streptococcal impetigo**

23

Fragile superficial bullae



24

13 – Skin and Soft Tissue Infections

Speaker: Helen Boucher, MD

Fragile Bullae in Epidermis

Diagnosis?

- Bullous impetigo

Etiology?

- *S. aureus*

25

Impetigo (“to attack”)

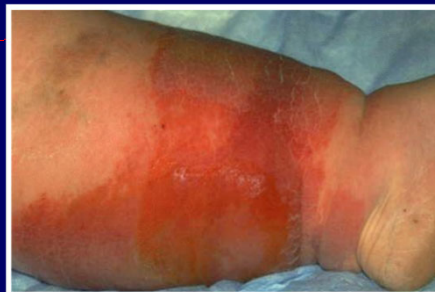- Bullous impetigo: *S. aureus*
- Non-bullous impetigo: *S. pyogenes, group A*
- So, empiric therapy aimed at *S. aureus* as could be MRSA
- Topical: topical antibiotic ointment (TAO), mupirocin, retapamulin
- Oral rarely needed
 - e.g, Clindamycin, doxycycline

26

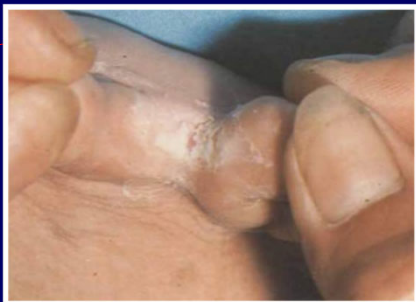Complications of *S. pyogenes, S. dysgalactiae* (Groups C&G) impetigo

- Post-streptococcal glomerulonephritis due to nephritogenic strains
- Rheumatic fever has “never” occurred after streptococcal impetigo

27



28



29

Acute onset of painful, rapidly spreading red plaque of inflammation involving epidermis, dermis, and subcutaneous fat
NO PURULENCE

Diagnosis?

30

13 – Skin and Soft Tissue Infections

Speaker: Helen Boucher, MD

Acute onset of painful, rapidly spreading red plaque of inflammation involving epidermis, dermis, and subcutaneous fat
NO PURULENCE
Diagnosis:
Erysipelas: Non-purulent cellulitis

31

Acute onset of painful, rapidly spreading red plaque of inflammation involving epidermis, dermis, and subcutaneous fat.
NO PURULENCE
Diagnosis:
• Erysipelas: Non-purulent cellulitis
Etiology?

32

Acute onset of painful, rapidly spreading red plaque of inflammation involving epidermis, dermis, and subcutaneous fat. NO PURULENCE
Diagnosis?
• Erysipelas: Non-purulent cellulitis
Etiology?
• Hemolytic Streptococci: Group A
• Now less common than groups C and G
• If on the face, could be *S. aureus*

33



34

Erysipelas (“Red Skin”)

- Acute onset of painful skin, rapid progression +/- lymphangitis
- Inflamed skin elevated, red, and demarcated
- Etiology: Streptococci—Groups A,B,C, & G (*S. pyogenes*, *S. agalactiae*, *S. dysgalactiae* subsp. *equisimilis*)
- Predisposition:
 - Lymphatic disruption, venous stasis

35

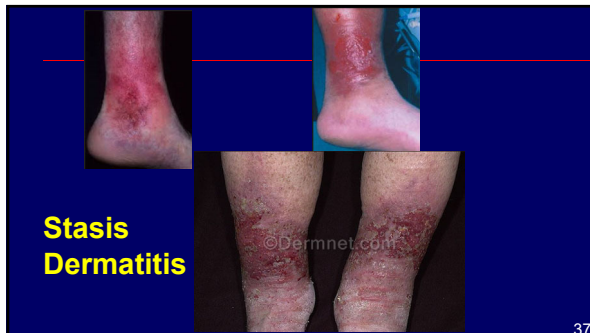Erysipelas and Cultures

- Usually no culture necessary
- Can isolate *S. pyogenes* from fungal-infected skin between toes
- Low density of organisms
 - Punch biopsy positive in only 20-30%
- Blood cultures positive in <= 5%
- Confused with stasis dermatitis

36

13 – Skin and Soft Tissue Infections

Speaker: Helen Boucher, MD



Stasis Dermatitis

- Looks like erysipelas; more frequent in obese individuals
- **No fever**
- Chronic, often **bilateral**, dependent edema
- Goes away with elevation
- **Does not respond to antimicrobials**
- Cadexomer iodine (IODOSORB) response rate 21% vs 5% for usual care

38

Treatment of Erysipelas (Non-purulent “cellulitis”)

- Elevation
- Topical antifungals between toes if tinea pedis present
- Penicillin, cephalosporins, clindamycin
- Avoid macrolides and TMP/SMX due to frequency of resistance

39

Cellulitis

- Without localization or preceding macro or micro trauma: usually Beta strep. (usually GAS), extremities > face, elsewhere
- With localization (cut, pustule, etc.) or preceding trauma: *S. aureus*

40

Severe Cellulitis

Microbiology: Streptococci (group A>B,C,G); less often *S. aureus*; rarely GNR

41

Recurrent Cellulitis

- Frequently non-group A streptococci (esp. B,G)
- Relapse > recurrence
- Prophylaxis:
 - Benzathine penicillin IM
 - Oral penicillin; other systemic antibiotics
 - Decolonization (nasal, elsewhere)

42

13 – Skin and Soft Tissue Infections

Speaker: Helen Boucher, MD

Risk Factors for Recurrent Erysipelas

- Lower Extremity
 - Post-bypass venectomy
 - Chronic lymphedema
 - Pelvic surgery
 - Lymphadenectomy
 - Pelvic irradiation
 - Chronic dermatophytosis
- Upper Extremity
 - Post-mastectomy/node dissection
- Breast
 - Post-breast conservation surgery, biopsy

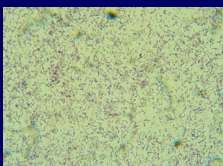
43

Erysipelothrix (Gram + rod)

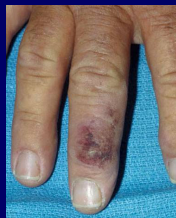- On finger after cut/abrasion exposure to infected animal (swine) or fish
- **Subacute erysipelas (erysipeloid)**
- Severe throbbing pain
- **Diagnosis: Culture of deep dermis (aspirate or biopsy)**
- **Treatment: Penicillin, cephalosporins, clindamycin, fluoroquinolone**

44

Erysipelothrix rhusiopathiae Infection



Gram stain of the organism (G+ rod) identified on culture



Resolving cellulitis caused by *Erysipelothrix rhusiopathiae*

45

Question #6

A 53 year old male construction worker has sudden onset of pain in his left calf. Within hours the skin and subcutaneous tissue of the calf are red, edematous and tender. Red “streaks” are seen spreading proximally

A short time later, patient is brought to the ER
Confused, vomiting, and hypotensive

- Temp 40C, diffuse erythema of the skin. Oxygen sat. 88% RA
- WBC 3000 with 25% polys and 50% band forms. Platelet count is 60,000

(Continued)

46

Question #6 Continued

Which one of the following is the most likely complication of the erysipelas?

- A. Bacteremic shock due to *S. pyogenes*?
- B. Toxic shock due to *S. pyogenes*?
- C. Bacteremic shock due to *S. aureus*?
- D. Toxic shock due to *S. aureus*?

47

Toxic Shock Syn. (TSS): Staph vs Strep

Feature	Staphylococcal	Streptococcal
Predisposition	Tampon, surgery; colonization	Cuts, Burns, Varicella, erysipelas
Focal Pain	No	Yes
Tissue necrosis/inflammation	Rare	Common
N/V, renal failure/DIC	Yes	Yes
Erythroderma	Very common	Less Common
Bacteremia	Very rare	60%
Mortality	<3%	30-70%

48


13 – Skin and Soft Tissue Infections

Speaker: Helen Boucher, MD

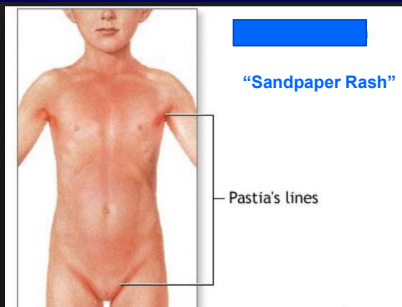
Sore throat and skin rash

- 20 year old man with 3 days of sore throat, fever, chills, and skin rash
- Rash is nonpruritic and involves abdomen, chest, back, arms, and legs
- Exam: Exudative tonsillitis, strawberry tongue, rash, and tender cervical lymph nodes

49



50



51

The most likely diagnosis ?

- Infectious mononucleosis
- Coxsackie hand, foot and mouth disease
- Scarlet fever
- *Arcanobacterium hemolyticum*

52

The most likely diagnosis ?

- Infectious mononucleosis
- Coxsackie hand, foot and mouth disease
- **Scarlet fever**
- *Arcanobacterium hemolyticum*

53

Question 7:

- 18 year old male taking anti- seizure meds for idiopathic epilepsy develops fluctuant tender furuncle on right arm
- He develops fever and generalized erythroderma; wherever he is touched, a bullous lesion develops
- **Skin biopsy shows intra-epidermal split in the skin**

54

13 – Skin and Soft Tissue Infections

Speaker: Helen Boucher, MD

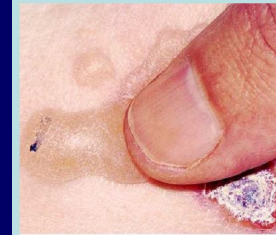Question #7

Which one of the following is the likely etiology of the skin bullae?

- A. *S. aureus* scalded skin syndrome?
- B. Bullous pemphigus?
- C. Drug-induced Toxic epidermal necrolysis (TEN)?
- D. *S. pyogenes* necrotizing fasciitis?

55

Nikolsky sign

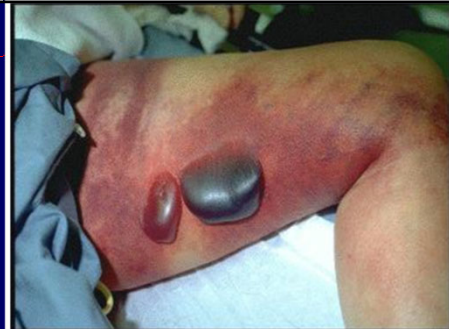

56

The Skin and Toxins of *S. aureus* and *S. pyogenes*

Organism	Toxin	Clinical Diagnosis
<i>S. aureus</i> colonization	TSST	TSS & Erythroderma
<i>S. aureus</i> colonization	Exfoliative toxin	Impetigo; scalded skin syndrome
<i>Strep. pyogenes</i> invasion	TSST	TSS; Erythroderma (not always)
<i>Strep. pyogenes</i>	Pyrogenic exotoxin	Pharyngitis; Scarlet Fever (sandpaper rash)

57



58

Erysipelas with loss of pain, hemorrhagic bullae, rapid progression..

Necrotizing fasciitis is due to which one ?

- a. Streptococcal fasciitis
- b. Staphylococcal fasciitis
- c. Clostridial infection
- d. Synergy between aerobe (*S. aureus*, *E. coli*) plus anaerobe (anaerobic strep, *Bacteroides sp*) equals Meleney's, Fournier's

Lancet ID 2015;15:109

59

Erysipelas with loss of pain, hemorrhagic bullae, rapid progression..

Necrotizing fasciitis is due to which one ?

- a. **Streptococcal fasciitis**
- b. Staphylococcal fasciitis
- c. Clostridial infection
- d. Synergy between aerobe (*S. aureus*, *E. coli*) plus anaerobe (anaerobic strep, *Bacteroides sp*) equals Meleney's, Fournier's

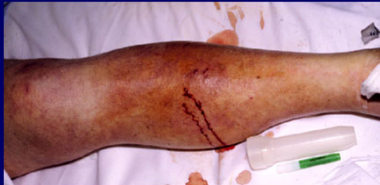Lancet ID 2015;15:109

60

13 – Skin and Soft Tissue Infections

Speaker: Helen Boucher, MD

Necrotizing Fasciitis: at the bedside



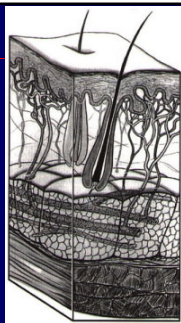
Sudden onset excruciating pain & systemic toxicity
 Note swelling of leg & 2 small purple bullae on anterior shin
 Pressures in the anterior/lateral compartments (blood at needle entry) elevated; surgical exploration performed

61

Treatment of necrotizing fasciitis

- Think of it
- Surgical debridement: sometimes several times needed to achieve source control
- Appropriate antimicrobial therapy

62



Anatomy	Syndrome
Epidermis	Erysipelas
Skin	Impetigo
	Folliculitis
Dermis	Ecthyma
	Furunculosis
	Carbuncle
	All of this is Cellulitis
Superficial fascia	Necrotizing fasciitis
Subcutaneous tissue	
Subcutaneous fat, Nerves, arteries, veins	
Deep fascia	
Muscle	Myonecrosis (clostridial and non-clostridial)

63

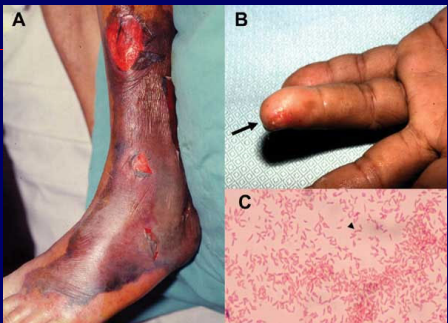Question #8

A 50-year-old male african american fisherman with known cirrhosis suffers an abrasion of his leg while harvesting oysters. Within hours, the skin is red, painful, and hemorrhagic bullae appear.

Which one of the following conditions predisposes to this infection?

- G6PD Deficiency
- Hemochromatosis
- Sickle cell disease
- Achlorhydria

64



65

Vibrio vulnificus

- Leading cause of shellfish (e.g., oysters)-associated deaths in USA
- Portal of entry: skin abrasions or GI
- Liver disease, **hemochromatosis**, and exposure to estuaries are major risk factors
- **Infected wounds manifest as bullae in 75%; primary bacteremia also occurs.**
- Treatment (look up): doxy plus ceftriaxone (alternative is an FQ)

66

13 – Skin and Soft Tissue Infections

Speaker: Helen Boucher, MD

Organisms Whose Growth is Stimulated by Excess Iron

- *Vibrio vulnificus* V
- *Escherichia coli* E
- *Listeria monocytogenes* L
- *Aeromonas hydrophilia* A
- *Rhizopus species (Mucor)* R
- *Yersinia enterocolitica* Y

Definition:
"The sails
of a ship"

67

Thank You!

- David Gilbert

- Our patients and their families

68

Questions, Comments?

- @hboucher3
- hboucher@tuftsmedicalcenter.org
- Helen.boucher@tufts.edu



69