


BR3 – Board Preview: Day 3

Moderator: Richard Whitley, MD




IDBR
**INFECTIOUS
DISEASE
BOARD REVIEW**

**AUGUST 20-24
2022**

Board Review: Day 3

Moderator: Richard Whitley, MD
Faculty: Drs. Bell, Dhanireddy, Ghanem, Thomas, Trautner, and Tunkel



BOARD REVIEW DAY 3

#31 A 44-year-old male living with HIV, a former intravenous drug user, is known for several years to be HBsAg positive and is on Bictegavir-emtricitabine-tenofovir alafenamide.

Which of the following would be most useful test for guiding the management of his hepatitis B:

- A) HBV resistance testing
- B) Hepatitis A serology
- C) Hepatitis D (delta) serology
- D) Hepatitis E serology
- E) Hepatitis G serology

#31 A 44-year-old male living with HIV, a former intravenous drug user, is known for several years to be HBsAg positive and is on Bictegravir-emtricitabine-tenofovir alafenamide.

Which of the following would be most useful test for guiding the management of his hepatitis B:

- A) HBV resistance testing
- B) Hepatitis A serology
- C) Hepatitis D (delta) serology *****
- D) Hepatitis E serology
- E) Hepatitis G serology

#32 A 20-year-old college student is seen in the student health service for a four-day illness with fever, sore throat and bilateral cervical lymph node swelling.

Which of the following statements is correct about this illness that has now persisted for four days?

- A) A negative Monospot rules out primary EBV infection
- B) EBV viral capsid IgM (+), EBV capsid IgG (-), EBNA (+) is consistent with primary EBV infection
- C) EBV viral capsid IgM (+), EBV capsid IgG (+), EBNA (-) is consistent with primary EBV infection
- D) A positive EBV PCR of peripheral blood would be diagnostic of acute mononucleosis

#32

A 20-year-old college student is seen in the student health service for a four-day illness with fever, sore throat and bilateral cervical lymph node swelling.

Which of the following statements is correct about this illness that has now persisted for four days?

- A) A negative Monospot rules out primary EBV infection
- B) EBV viral capsid IgM (+), EBV capsid IgG (-), EBNA (+) is consistent with primary EBV infection
- C) EBV viral capsid IgM (+), EBV capsid IgG (+), EBNA (-) is consistent with primary EBV infection *****
- D) A positive EBV PCR of peripheral blood would be diagnostic of acute mononucleosis

#33

A 17-year-old adolescent woman presented for care because of a ten-day history of increasing abdominal pain, accompanied by low grade fever the past two days.

The pain was mostly in the right upper quadrant, worse on deep breathing.

On deep inspiration, the pain was felt in her right shoulder. She also reported an abnormal yellow vaginal discharge. Her menses has been normal. No dysuria was reported.

She reported vaginal intercourse with a several males who did not use condoms.

#33 On exam, her vital signs were normal except for a temperature of 38.5C.

She had marked tenderness in the right upper quadrant and some dull tenderness over the lower abdomen bilaterally.

WBC 11,800 with normal liver chemistries.

Abdominal ultrasound found no evidence of cholecystitis or liver abscess. Urine pregnancy test was negative.

#33 Which test is most likely to establish the correct diagnosis?

A) CT of abdomen and pelvis with oral and IV contrast

B) Laparoscopy

C) Cervical PCR for HSV

D) Liver biopsy

E) Cervical NAAT for Chlamydia trachomatis

#33 Which test is most likely to establish the correct diagnosis?

- A) CT of abdomen and pelvis with oral and IV contrast
- B) Laparoscopy
- C) Cervical PCR for HSV
- D) Liver biopsy
- E) Cervical NAAT for Chlamydia trachomatis *****

#34 A 23-year-old monogamous man presents to clinic asking about the HPV vaccine.

He states he has been in a monogamous relationship with the same man for three years.

He has no allergies and has never received an HPV vaccine.

IDBR
INFECTIOUS
DISEASE
BOARD REVIEW

AUGUST 20-24
2022

BOARD REVIEW DAY 3

#34 Which of the following is correct?

- A) He is too old for the catch-up schedule for the HPV immunization of boys
- B) If he is monogamous, he is at low risk for the acquisition of HPV and does not need to be immunized
- C) He should begin immunization with the nine-valent vaccine
- D) He should begin immunization with either the bi-valent or the nine valent vaccine

IDBR
INFECTIOUS
DISEASE
BOARD REVIEW

AUGUST 20-24
2022

BOARD REVIEW DAY 3

#34 Which of the following is correct?

- A) He is too old for the catch-up schedule for the HPV immunization of boys
- B) If he is monogamous, he is at low risk for the acquisition of HPV and does not need to be immunized
- C) He should begin immunization with the nine-valent vaccine *****
- D) He should begin immunization with either the bi-valent or the nine valent vaccine

#35 You've been charged with leading a program to decrease ventilator-associated pneumonia (VAP) rates in the medical intensive care unit.

You gather a multidisciplinary team with nurses, doctors, respiratory therapists, pharmacists, physical therapists, and the unit clerk.

#35 Which of the following initiatives is most likely to lower VAP rates and improve outcomes for patients on mechanical ventilation?

- A) Begin bathing patients twice daily with povidone iodine
- B) Provide oral care with 0.12% chlorhexidine solution twice daily
- C) Switch to using silver coated endotracheal tubes for all patients
- D) Introduce a protocol to minimize sedation and increase patient mobility
- E) Put patients in the Trendelenburg position in order to encourage drainage of respiratory secretions away from the lungs

- #35** Which of the following initiatives is most likely to lower VAP rates and improve outcomes for patients on mechanical ventilation?
- A) Begin bathing patients twice daily with povidone iodine
 - B) Provide oral care with 0.12% chlorhexidine solution twice daily
 - C) Switch to using silver coated endotracheal tubes for all patients
 - D) Introduce a protocol to minimize sedation and increase patient mobility *****
 - E) Put patients in the Trendelenburg position in order to encourage drainage of respiratory secretions away from the lungs

- #36** A 72-year-old man with a history of diabetes and obesity presents to his primary care physician with a complaint of foul-smelling, cloudy urine.
- He does not have dysuria or voiding difficulties, but he reports recent loss of 10 pounds without dieting.
- He has not seen a urologist or had any urinary instrumentation. No recent fevers noted, and he is afebrile at this visit.
- Urinalysis shows 100 WBC/HPF and many bacteria; culture grows *E. coli* sensitive to trimethoprim-sulfamethoxazole. He is treated with a 7-day course of trimethoprim-sulfamethoxazole.

#36 He returns to his primary care physician a week after completing the course of antibiotics and reports his urine is still cloudy and foul-smelling. Now he notices that his urine has bubbles towards the end of emptying his bladder. He has no other urinary symptoms.

CBC shows anemia and mild leukocytosis. Repeat urine culture grows *Proteus*, sensitive to trimethoprim-sulfamethoxazole, ceftriaxone, fosfomycin and ertapenem. Stool is positive for occult blood.

His vital signs are normal on physical examination, but he is slightly pale. He does not have suprapubic tenderness.

#36 Which of the following is the most appropriate management?

- A) 14-day course of oral trimethoprim-sulfamethoxazole
- B) IV ertapenem
- C) Ultrasound of prostate
- D) Abdominal/pelvic CT scan with rectal contrast
- E) Oral Fosfomycin

#36 Which of the following is the most appropriate management?

- A) 14-day course of oral trimethoprim-sulfamethoxazole
- B) IV ertapenem
- C) Ultrasound of prostate
- D) Abdominal/pelvic CT scan with rectal contrast *****
- E) Oral Fosfomycin

#37 You are asked to see a 67 yr old man who had been admitted for headache and increasing confusion over the past week.

Earlier today he had been found to have a 4.5 cm right parietal brain abscess on CT. On that CT the right mastoid was full of fluid.

On exam, he is afebrile, unable to respond to verbal stimuli but moves all extremities. Neurological exam is otherwise unremarkable.

Optic fundi cannot be visualized because of cataracts and the right external auditory canal is blocked with cerumen.

#37 The patient appeared to wince on pressure over the right mastoid process. You recommend urgently which of the following:

- A) Lumbar puncture
- B) ENT consultation for possible otitis media
- C) Neurosurgical aspiration of the abscess
- D) Neurosurgical resection of the abscess
- E) Trial of empirical antibiotics

#37 The patient appeared to wince on pressure over the right mastoid process. You recommend urgently which of the following:

- A) Lumbar puncture
- B) ENT consultation for possible otitis media
- C) Neurosurgical aspiration of the abscess *****
- D) Neurosurgical resection of the abscess
- E) Trial of empirical antibiotics

#38

A 26-year-old cis-gender man develops mild burning on urination without any significant discharge. He is tested by Nucleic Acid Amplification Testing (NAAT) of his urine and is negative for gonorrhea and Chlamydia.

Several urethral discharge samples evaluated by wet mount preparations demonstrate > 5 WBCs/HPF but no organisms were observed on Gram's staining.

His male partner is asymptomatic and had negative gonorrhea and chlamydia testing.

The patient has no other symptoms and feels well otherwise. An HLA B-27 histocompatibility antigen is negative.

One course of treatment with doxycycline has been unsuccessful.

#38

A likely cause of this patient's complaints is:

- A) Chlamydia trachomatis
- B) Neisseria gonorrhea
- C) Trichomonas vaginalis
- D) Mycoplasma genitalium
- E) Reiter's Syndrome (reactive arthritis)

#38 A likely cause of this patient's complaints is:

- A) *Chlamydia trachomatis*
- B) *Neisseria gonorrhoea*
- C) *Trichomonas vaginalis*
- D) *Mycoplasma genitalium* *****
- E) Reiter's Syndrome (reactive arthritis)

#39 A 37-year-old female nurse comes to your office to get advice. She recently spent four weeks on a mission trip in Chad, and one week prior to coming back to the United States she received a minor bite on her lower leg from a stray dog.

She cleaned the wound and took a few days of amoxicillin/clavulanic acid.

Efforts to obtain rabies vaccine and rabies immune globulin in Chad were unsuccessful.

The wound healed without complication and she is feeling well.

#39 She had a tetanus shot last year.

When she was a child living overseas she had serum sickness after receiving horse tetanus immune globulin.

She has been back in the United States for a week, so it has been two weeks since she had the bite and the site is not inflamed.

#39 What treatment is indicated?

- A) Nothing else is indicated at this late date
- B) Rabies vaccination only
- C) Rabies immune globulin in the buttocks and rabies vaccination
- D) Rabies immune globulin in the bite site and rabies vaccination
- E) Rabies vaccine and skin testing for allergy to horse serum prior to administration of rabies immune globulin

#39 What treatment is indicated?

- A) Nothing else is indicated at this late date
- B) Rabies vaccination only
- C) Rabies immune globulin in the buttocks and rabies vaccination
- D) Rabies immune globulin in the bite site and rabies vaccination *****
- E) Rabies vaccine and skin testing for allergy to horse serum prior to administration of rabies immune globulin

#40 A 66-year-old man comes to the Emergency Room with severe nausea and vomiting for 6 hours with diarrhea for 2 hours.

He has been in relatively good health but has adult-onset diabetes, mild congestive heart failure, and hypercholesterolemia.

He has no history of prior GI problems and no one else in his family is ill, including the two toddlers that his wife cares for in his home. On physical examination, he is febrile to 38.3°C, BP 150/80, RR 20, P 100.

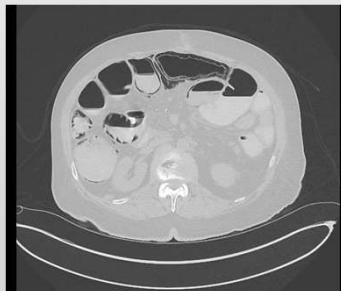He has a mildly tender abdomen with no rebound.

#40

Laboratory:

- WBC 11,000 (60% polys), Hg 13 g/dl, Plat 220,000
- Chemistry Profile: Na 145 meq/L, K 3.8 meq/L, CO₂ 22 meq/L, BUN 20 mg/dl, Creat 2.0 mg/dl, Lactate 0.9 mmol/L
- Stool cultures sent: rotavirus screen negative

CT Scan:



The ER starts vancomycin and ciprofloxacin plus metronidazole and calls you for a consultation.

#40

What is the appropriate response to the finding of pneumatosis intestinalis in this patient?

- A) Immediate laparotomy
- B) Change antibiotic regimen to meropenem and vancomycin
- C) Add caspofungin to ciprofloxacin and metronidazole
- D) Colonoscopy
- E) Observation of clinical course: no change in current management

#40 What is the appropriate response to the finding of pneumatosis intestinalis in this patient?

- A) Immediate laparotomy
- B) Change antibiotic regimen to meropenem and vancomycin
- C) Add caspofungin to ciprofloxacin and metronidazole
- D) Colonoscopy
- E) Observation of clinical course: no change in current management *****

#41 A 19-year-old female in her 10th week of pregnancy was seen in the obstetrics clinic for routine follow-up when the history was elicited that she had taken care of her friend's child all day three days prior and that child had now developed chickenpox.

The patient was a recent immigrant from rural Nigeria, had no recollection of chickenpox or shingles and no knowledge that she had ever been immunized or exposed to chickenpox previously.

The OB clinic has called to see if anything should be given as post-exposure prophylaxis.

You cannot obtain a varicella titer for at least 3 more days since this call comes...Friday afternoon.

IDBR
INFECTIOUS
DISEASE
BOARD REVIEW

AUGUST 20-24
2022

BOARD REVIEW DAY 3

#41 Your advice is which of the following:

- A) Nothing
- B) Chickenpox vaccine
- C) Varicella zoster immune globulin
- D) Varicella zoster immune globulin plus chickenpox vaccine
- E) Intravenous immune globulin (IVIG)

IDBR
INFECTIOUS
DISEASE
BOARD REVIEW

AUGUST 20-24
2022

BOARD REVIEW DAY 3

#41 Your advice is which of the following:

- A) Nothing
- B) Chickenpox vaccine
- C) Varicella zoster immune globulin *****
- D) Varicella zoster immune globulin plus chickenpox vaccine
- E) Intravenous immune globulin (IVIG)

#42 A 28-year-old woman just finished a course of glecaprevir and pibrentasvir for chronic HCV infection.

12 weeks after finishing this guideline recommended course, her HCV RNA is negative.

She was F0 on elastography pre-treatment and her post-treatment liver function tests are normal.

#42 Which counseling is most relevant to this patient:

- A) Avoid all alcohol use
- B) Avoid statins or other drugs that cause hepatotoxicity
- C) Avoid needle sharing or unprotected sex with HCV infected persons
- D) Avoid pregnancy for 24 months to eliminate the risk of perinatal transmission from the HCV that was treated
- E) Avoid ibuprofen

- #42** Which counseling is most relevant to this patient:
- A) Avoid all alcohol use
 - B) Avoid statins or other drugs that cause hepatotoxicity
 - C) Avoid needle sharing or unprotected sex with HCV infected persons *****
 - D) Avoid pregnancy for 24 months to eliminate the risk of perinatal transmission from the HCV that was treated
 - E) Avoid ibuprofen

- #43** A 55-year-old man is brought to the emergency room because of increasingly severe back pain of two days' duration, precipitated by loading some grain sacks onto his truck.
- He has been seen in the past because of obesity, poorly controlled type 2 diabetes mellitus and hypertension.
- Admission blood cultures have grown MSSA.
- Nafcillin and a TTE have been ordered.

#43 MRI has found osteomyelitis of vertebral bodies T12 and L1, with a contiguous epidural abscess impinging on the spinal cord.

On your examination, temperature is 39C, pulse 120 and BP 160/90.

The patient is alert but has severe back pain.

He is unable to walk because of pain but has weakness in both legs and absent deep tendon reflexes in both legs.

#43 The next thing that should be done is which of the following:

- A) Surgical decompression of the spinal cord
- B) Aspiration of the epidural abscess by interventional radiology
- C) Nafcillin is sufficient for the present
- D) Add rifampin to nafcillin
- E) High dose dexamethasone

- #43** The next thing that should be done is which of the following:
- A) Surgical decompression of the spinal cord *****
 - B) Aspiration of the epidural abscess by interventional radiology
 - C) Nafcillin is sufficient for the present
 - D) Add rifampin to nafcillin
 - E) High dose dexamethasone

- #44** A 25-year-old graduate student is seen for penile ulcers. The ulcers have been present for two weeks and are painful. He says the ulcers began as “red bumps” that developed into “pimples” and then eroded into ulcers.
- Over the past 2-3 days he noted a tender lump in his groin.
- The problem began during a trip to Africa from which he returned just three days ago. While in Africa he had vaginal intercourse with several commercial sex workers while he was inebriated and did not always use a condom.

#44 On exam he is afebrile and findings are confined to his genital area.

There are two 1cm adjacent “kissing” ulcers in the coronal sulcus. They are tender and filled with a yellow purulent exudate.

There is a tender, large lymph node in the left groin.

#44 Which one of the following is the most likely cause of his problem?

- A) *Treponema pallidum*
- B) *Herpes simplex*
- C) *Chlamydia trachomatis*
- D) *Haemophilus ducreyi*
- E) *Klebsiella (Calymmatobacterium) granulomatis*

#44 Which one of the following is the most likely cause of his problem?

- A) *Treponema pallidum*
- B) Herpes simplex
- C) *Chlamydia trachomatis*
- D) *Haemophilus ducreyi* *****
- E) *Klebsiella (Calymmatobacterium) granulomatis*

#45 A 46-year-old man with poorly controlled diabetes presented with fever and acute onset of urinary retention.

In the emergency room, a urinalysis was sent, which revealed 55 WBC/HPF, 10 RBC/HPF. Urine culture, unfortunately, was not performed.

He was diagnosed with UTI and sent home with an indwelling Foley catheter and 10 days of ciprofloxacin. A follow-up visit with urology was requested but was not scheduled to occur until 2 months later.

#45 One month after his ER visit, he came to the clinic to see his regular physician. The urinary catheter was still in place.

He reported feeling hot/sweaty with shaking chills for the past 2 nights, and he also reported new back pain. His measured temperature in the clinic was 104°F.

On examination, he had left-sided costovertebral angle tenderness.

He was admitted to the hospital and started on ciprofloxacin. The urinary catheter was removed, and his post-void residual volume was <100 cc of urine.

#45 His admission urine culture grew *Klebsiella pneumoniae* and *Serratia marcescens*.

His admission blood culture (one set) grew *Serratia marcescens* in both bottles. Both organisms were sensitive to ciprofloxacin.

On hospital day 3, his maximum temperature was 101°F, and he developed right testicular pain/swelling.

Examination revealed a tender mass in the posterior aspect of the right scrotum, with overlying erythema. Scrotal ultrasound revealed right epididymitis.

- #45** What is the next appropriate step?
- A) Urology consult
 - B) Continue ciprofloxacin
 - C) Abdominal/pelvic CT scan with IV contrast
 - D) Renal ultrasound

- #45** What is the next appropriate step?
- A) Urology consult
 - B) Continue ciprofloxacin *****
 - C) Abdominal/pelvic CT scan with IV contrast
 - D) Renal ultrasound