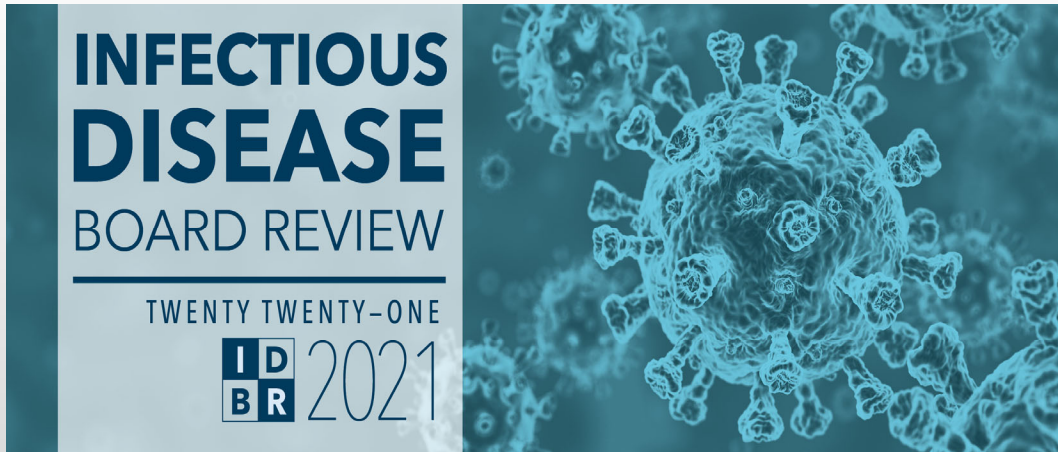

55 – Daily Question Preview: Day 5

Moderator: Kieren Marr, MD



Daily Question Preview: Day 5

Moderator: Kieren Marr, MD



5.1 35-year-old woman with AML day 15 after induction therapy.


Fever, chills, diffuse erythematous rash. Blood culture + GPC in chains

Exam – 100/62, HR 120, grade 2 oral mucositis, and a diffuse, blanching, erythematous rash. CXR - bilateral diffuse infiltrates.

She is receiving levofloxacin and acyclovir.

55 – Daily Question Preview: Day 5

Moderator: Kieren Marr, MD




INFECTION DISEASE BOARD REVIEW
THE GREAT NORTH EAST
15 2021

PREVIEW QUESTION

5.1 This is most consistent with infection with which of the following organisms?

- A) *Streptococcus pneumoniae*
- B) Coagulase-negative *Staphylococcus*
- C) *Enterococcus faecalis*
- D) *Streptococcus mitis*
- E) *Stomatococcus mucilaginosus*



INFECTION DISEASE BOARD REVIEW
THE GREAT NORTH EAST
15 2021


PREVIEW QUESTION

5.1 This is most consistent with infection with which of the following organisms?

- A) *Streptococcus pneumoniae*
- B) Coagulase-negative *Staphylococcus*
- C) *Enterococcus faecalis*
- D) *Streptococcus mitis***
- E) *Stomatococcus mucilaginosus*

55 – Daily Question Preview: Day 5

Moderator: Kieren Marr, MD



INFECTION DISEASE BOARD REVIEW
THE INSTITUTE FOR BOARD REVIEW
IDB 2021


PREVIEW QUESTION

5.2 70-year-old woman with AML, neutropenic for 15 days, s/p induction chemotherapy develops fever, diarrhea, and abdominal pain.

Exam - decreased bowel sounds and tenderness with deep palpation in her RLQ.

CT shows inflammation in cecum. Levofloxacin and fluconazole prophylaxis.

4 days prior to her admission for chemotherapy, she ate Chinese food with fried rice.



INFECTION DISEASE BOARD REVIEW
THE INSTITUTE FOR BOARD REVIEW
IDB 2021



PREVIEW QUESTION

5.2 Which is the most likely etiology?

- A) Norovirus
- B) *Clostridioides (Clostridium) difficile*
- C) Mixed anaerobic and aerobic bacteria
- D) *Candida albicans*
- E) *Bacillus cereus*

55 – Daily Question Preview: Day 5



Moderator: Kieren Marr, MD



PREVIEW QUESTION

5.2 Which is the most likely etiology?

- A) Norovirus
- B) *Clostridioides (Clostridium) difficile*
- C) Mixed anaerobic and aerobic bacteria**
- D) *Candida albicans*
- E) *Bacillus cereus*



PREVIEW QUESTION

5.3 35-year-old F, 80 days after allogeneic BMT with 5 days of anorexia, nausea, epigastric pain, and diarrhea.



CMV D-/R+, HSV+, VZV+.

Exam: Faint maculopapular rash on upper body. Afebrile.

Meds: acyclovir, TMP-SMX and fluconazole.
ANC 1000, ALC 250. LFTs normal.

55 – Daily Question Preview: Day 5



Moderator: Kieren Marr, MD



PREVIEW QUESTION

5.3 What is the most appropriate initial work-up and management?

- A) Perform serum VZV PCR
- B) Empiric corticosteroid treatment
- C) Send C. diff toxin and start oral vancomycin
- D) CMV PCR, stool C. diff, bacterial culture
- E) #D and upper, lower endoscopy





PREVIEW QUESTION

5.3 What is the most appropriate initial work-up and management?

- A) Perform serum VZV PCR
- B) Empiric corticosteroid treatment
- C) Send C. diff toxin and start oral vancomycin
- D) CMV PCR, stool C. diff, bacterial culture
- E) #D and upper, lower endoscopy**

55 – Daily Question Preview: Day 5

Moderator: Kieren Marr, MD



PREVIEW QUESTION

5.4 40-year-old male. Day 60 after allogeneic BMT from unrelated donor, with bloody urine for 6 days.

Has skin GVHD, receiving a prednisone taper (1 mg/kg/day). Exam, faint diffuse erythematous rash. Cr 1. LFTs normal. CMV pcr negative.



PREVIEW QUESTION

5.4 The most likely etiology is:

- A) Cyclophosphamide
- B) CMV
- C) EBV
- D) BK
- E) JC virus

55 – Daily Question Preview: Day 5

Moderator: Kieren Marr, MD

INFECTIOUS
DISEASE
BOARD REVIEW
THE MOST IMPORTANT CASES
IN 2021

PREVIEW QUESTION

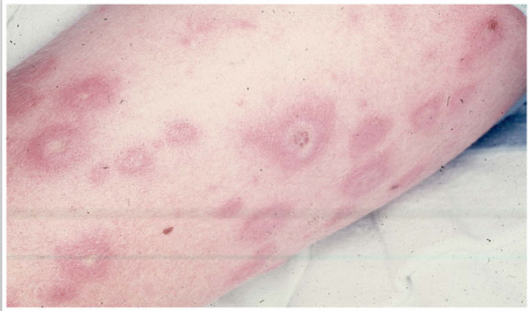
5.4 The most likely etiology is:

- A) Cyclophosphamide
- B) CMV
- C) EBV
- D) BK**
- E) JC virus

INFECTIOUS
DISEASE
BOARD REVIEW
THE MOST IMPORTANT CASES
IN 2021



PREVIEW QUESTION

5.5 35-year-old male 68 days post allogeneic bone marrow transplantation for myelodysplastic syndrome, receiving methylprednisolone 500 mg for Grade III GVHD of the gastrointestinal tract developed fever, several painful, red skin nodules and a blood culture growing a mold.



55 – Daily Question Preview: Day 5



Moderator: Kieren Marr, MD



PREVIEW QUESTION

5.5 The most likely fungus is which of the following:

- A) *Scedosporium apiospermum* (*Pseudallescheria boydii*)
- B) *Lomentospora* (*Scedosporium*) *prolificans*
- C) *Apophysomyces elegans*
- D) *Fusarium multifforme*
- E) *Alternaria alternata*



PREVIEW QUESTION

5.5 The most likely fungus is which of the following:

- A) *Scedosporium apiospermum* (*Pseudallescheria boydii*)
- B) *Lomentospora* (*Scedosporium*) *prolificans*
- C) *Apophysomyces elegans*
- D) *Fusarium multifforme***
- E) *Alternaria alternata*

55 – Daily Question Preview: Day 5

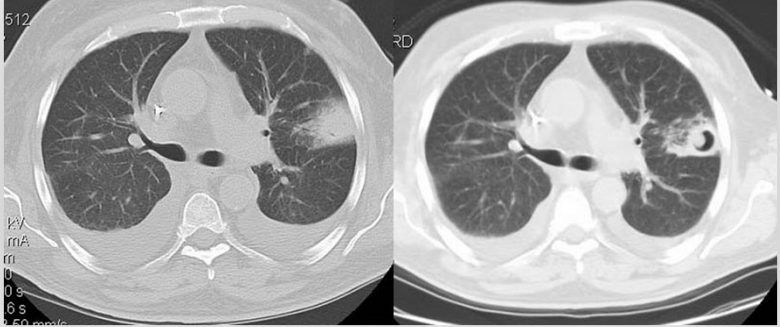
Moderator: Kieren Marr, MD

INFECTIOUS DISEASE BOARD REVIEW
MAY 2021

PREVIEW QUESTION

5.6 32-year-old male with allogeneic hematopoietic stem cell transplant recipient for AML, developed graft versus host disease, given high dose prednisone, discharged and re-admitted for fever not responding to antibacterial antibiotics.

These two chest CT's, were taken at admission and a week later while he was responding to voriconazole.



INFECTIOUS DISEASE BOARD REVIEW
MAY 2021


PREVIEW QUESTION

5.6 The most likely source of infection is:

- A) Dirt from his garden
- B) His oral flora
- C) Contaminated food
- D) Intravenous catheter

55 – Daily Question Preview: Day 5

Moderator: Kieren Marr, MD




INFECTION DISEASE BOARD REVIEW
THE MOST IMPORTANT CASES IN INFECTION
10th Edition 2021

PREVIEW QUESTION

5.6 The most likely source of infection is:

- A) Dirt from his garden**
- B) His oral flora
- C) Contaminated food
- D) Intravenous catheter



INFECTION DISEASE BOARD REVIEW
THE MOST IMPORTANT CASES IN INFECTION
10th Edition 2021

PREVIEW QUESTION


5.7 54-year-old male 60 days post-cardiac transplant was treated for rejection with steroids when fever and a non-tender anterior cervical mass appeared.

Biopsy showed nodal replacement by lymphocytes, many of which stained positively for Epstein-Barr virus as well as for the B cell marker, CD20.

His plasma EBV viral load was 10,000 copies /ml.

55 – Daily Question Preview: Day 5

Moderator: Kieren Marr, MD




INFECTION DISEASE BOARD REVIEW
MAY 2021

PREVIEW QUESTION

5.7 The most appropriate treatment for this condition is:

- A) Cidofovir
- B) Ganciclovir
- C) Acyclovir
- D) Cyclophosphamide
- E) Rituximab



INFECTION DISEASE BOARD REVIEW
MAY 2021


PREVIEW QUESTION

5.7 The most appropriate treatment for this condition is:

- A) Cidofovir
- B) Ganciclovir
- C) Acyclovir
- D) Cyclophosphamide
- E) Rituximab**

55 – Daily Question Preview: Day 5

Moderator: Kieren Marr, MD



INFECTION DISEASE BOARD REVIEW
TREATMENT CASE
Q5 2021


PREVIEW QUESTION

5.8 52-year-old female S/P cadaveric renal transplant receiving tacrolimus, prednisone and mycophenylate.

Week 30 post transplant serum creatinine rose from 1.5 to 2.3 mg/dl.

Tacrolimus levels were in therapeutic range.

Urinalysis revealed one plus protein and no cells or casts.




INFECTION DISEASE BOARD REVIEW
TREATMENT CASE
Q5 2021

PREVIEW QUESTION

5.8 Which would be most helpful in understanding if BK virus was causing her renal failure?

- A) Presence of decoy cells in urine cytology
- B) Urine BK viral load
- C) Urine culture for BK virus
- D) Plasma BK viral load
- E) Demonstration of BK inclusions in renal tubular epithelium on renal biopsy




INFECTIOUS DISEASE BOARD REVIEW
THE GREAT NORTH WEST
10th 2021

PREVIEW QUESTION

5.8 Which would be most helpful in understanding if BK virus was causing her renal failure?

- A) Presence of decoy cells in urine cytology
- B) Urine BK viral load
- C) Urine culture for BK virus
- D) Plasma BK viral load
- E) Demonstration of BK inclusions in renal tubular epithelium on renal biopsy**



INFECTIOUS DISEASE BOARD REVIEW
THE GREAT NORTH WEST
10th 2021


PREVIEW QUESTION

5.9 Liver transplant recipient presented 21 days post transplant with confusion, tremors, lethargy, anorexia

- On bactrim & valganciclovir prophylaxis
- Rapid progressive neurologic decline → agitation & delirium → intubation
- Blood & urine cultures: negative
- CSF: lymphocytic pleocytosis (25 WBCs/mm³) & elevated protein
 - Gram stain, bacterial, fungal cultures negative

55 – Daily Question Preview: Day 5

Moderator: Kieren Marr, MD




INFECTION DISEASE BOARD REVIEW
THE GREAT NORTHWEST
MAY 2021

PREVIEW QUESTION

5.9

- Brain MRI: non-revealing
- Empiric intravenous ganciclovir, vancomycin, ceftriaxone & ampicillin
- Day 6 Repeat MRI: diffuse encephalitis
- Expired 13 days after neurologic symptom onset
- Donor was previously healthy presenting with subarachnoid hemorrhage
 - Toxicology screen: + cocaine & marijuana
 - Brain CT: expanding subarachnoid hemorrhage
 - Recently on camping trip



INFECTION DISEASE BOARD REVIEW
THE GREAT NORTHWEST
MAY 2021



PREVIEW QUESTION

5.9 This presentation is most consistent with:

- A) CMV encephalitis
- B) HHV6 encephalitis
- C) VZV encephalitis
- D) Rabies encephalitis
- E) Cryptococcal meningitis

55 – Daily Question Preview: Day 5



Moderator: Kieren Marr, MD



PREVIEW QUESTION

5.9 This presentation is most consistent with:

- A) CMV encephalitis
- B) HHV6 encephalitis
- C) VZV encephalitis
- D) Rabies encephalitis**
- E) Cryptococcal meningitis



PREVIEW QUESTION


5.10 55-year-old male

6d fever, malaise, severe headache, dry cough, myalgia

- PMH: HTN
- Meds: Lisinopril/HCT
- SH: Married, suburban Maryland
 - Works in long-term care facility
 - Visited pet shop 10d earlier
 - Parakeets, cockatiels
 - Confided infidelity in last month

55 – Daily Question Preview: Day 5


Moderator: Kieren Marr, MD



INFECTIOUS
DISEASE
BOARD REVIEW
— PRESENTATIONS —
100
Qs
2021

PREVIEW QUESTION

5.10 Exam: ill-toxic, 40°C P88
BP100/70 RR18 O2 97% RA
Lungs: clear
Neck: supple
Cor: no murmurs
Skin: no rashes
LP: pending
Labs: WBC 5200, 26% B
Sputum: 1+ PMNs, no organisms

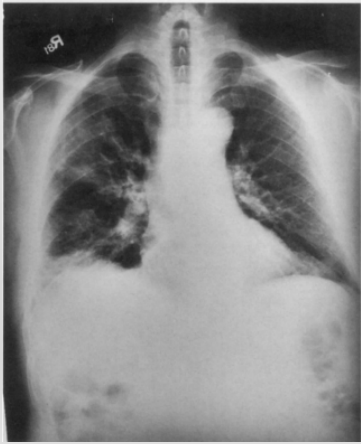


INFECTIOUS
DISEASE
BOARD REVIEW
— PRESENTATIONS —
100
Qs
2021

PREVIEW QUESTION

5.10 Which antibiotic will lead to the most rapid improvement?

- A) Ceftriaxone
- B) Gentamicin
- C) Doxycycline
- D) Trimethoprim/sulfamethoxazole



55 – Daily Question Preview: Day 5

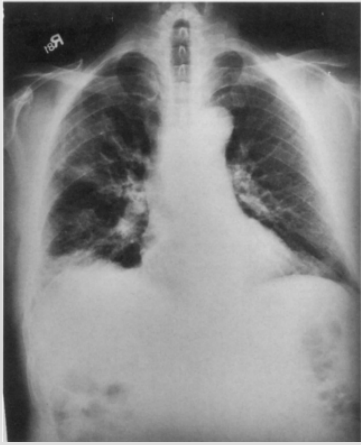
Moderator: Kieren Marr, MD

INFECTIOUS DISEASE BOARD REVIEW
THE INFECTION SOCIETY OF AMERICA
IS 2021

PREVIEW QUESTION

5.10 Which antibiotic will lead to the most rapid improvement?

- A) Ceftriaxone
- B) Gentamicin
- C) Doxycycline**
- D) Trimethoprim/sulfamethoxazole



INFECTIOUS DISEASE BOARD REVIEW
THE INFECTION SOCIETY OF AMERICA
IS 2021

PREVIEW QUESTION


5.11

18F c/o fever, dry hacking cough, malaise x 3d

Allergy: erythromycin (N/V)

Appears well, T38°C, RR 16, P 80, BP 110/70

- Oropharynx: Normal
- TMs: Normal
- Chest: Some crackles left lower lobe



55 – Daily Question Preview: Day 5

Moderator: Kieren Marr, MD

5.11

- Azithromycin prescribed
- Next day, full body rash and mucosal lesions develop



PREVIEW QUESTION

5.11


What is the most likely etiology?

- A) *Mycoplasma pneumoniae*
- B) Enterovirus D68
- C) Measles
- D) Lyme disease
- E) Drug reaction (azithromycin)

PREVIEW QUESTION

55 – Daily Question Preview: Day 5

Moderator: Kieren Marr, MD




INFECTION DISEASE BOARD REVIEW
THE GREAT NORTHWEST
10th 2021

PREVIEW QUESTION

5.11 What is the most likely etiology?

- A) *Mycoplasma pneumoniae***
- B) Enterovirus D68
- C) Measles
- D) Lyme disease
- E) Drug reaction (azithromycin)



INFECTION DISEASE BOARD REVIEW
THE GREAT NORTHWEST
10th 2021

PREVIEW QUESTION

5.12 62-year-old male living in an exurb of Phoenix, Arizona presents in early September with a three day history of fever, myalgia, headache and rash.



He works as a lineman for a utility company.

He lives with his family in an older adobe home with dogs.

He has beginnings of petechial features on the wrists and ankles.

55 – Daily Question Preview: Day 5



Moderator: Kieren Marr, MD



PREVIEW QUESTION

5.12 Which of the following is the most likely diagnosis?

- A) Human Monocytic Ehrlichiosis (HME)
- B) Human Granulocytic Anaplasmosis (HGA)
- C) Babesiosis
- D) Rocky Mountain Spotted Fever (RMSF)
- E) Tularemia



PREVIEW QUESTION

5.12 Which of the following is the most likely diagnosis?

- A) Human Monocytic Ehrlichiosis (HME)
- B) Human Granulocytic Anaplasmosis (HGA)
- C) Babesiosis
- D) Rocky Mountain Spotted Fever (RMSF)**
- E) Tularemia

55 – Daily Question Preview: Day 5

Moderator: Kieren Marr, MD

INFECTIOUS
DISEASE
BOARD REVIEW
— PREVIEW QUESTION —
10 2021

PREVIEW QUESTION



5.13

48-year-old male presents in October with fever and rash

Supervisor for apartment building in Queens, NY. Lives in cellar apt.

Exam: T 390C
brown-black 8mm eschar on RLE
~30 papulovesicular lesions on trunk



INFECTIOUS
DISEASE
BOARD REVIEW
— PREVIEW QUESTION —
10 2021

PREVIEW QUESTION


5.13

Which of the following is the most likely etiologic agent?

- A) *R. rickettsii*
- B) *R. parkeri*
- C) *R. akari*
- D) *R. conorii*
- E) *Borrelia recurrentis*

55 – Daily Question Preview: Day 5

Moderator: Kieren Marr, MD




INFECTION DISEASE BOARD REVIEW
THE GREAT NORTHWEST
ID 2021

PREVIEW QUESTION

5.13 Which of the following is the most likely etiologic agent?

- A) *R. rickettsii*
- B) *R. parkeri*
- C) *R. akari***
- D) *R. conorii*
- E) *Borrelia recurrentis*



INFECTION DISEASE BOARD REVIEW
THE GREAT NORTHWEST
ID 2021

PREVIEW QUESTION

5.14 43-year-old visited southern Missouri on vacation, returns 7d later with fever, headache and diffuse myalgia x 3d


Physical examination: no findings

Laboratory evaluation :

- WBC: 2.1/mm³ (80% PMNs, 10% lymphocytes, 8% monocytes)
- Hemoglobin: 7.0 g/dL, hematocrit: 24%
- Platelets: 105,000/mm³
- AST: 364 U/L, ALT: 289 U/L
- renal function: normal

55 – Daily Question Preview: Day 5

Moderator: Kieren Marr, MD




INFECTION DISEASE BOARD REVIEW
THE MOST IMPORTANT CASES IN 2021

PREVIEW QUESTION

5.14 Which of the following is the most likely etiologic agent?

- A) *Anaplasma phagocytophilum*
- B) *Ehrlichia chaffeensis*
- C) *Borrelia hermsii*
- D) *Babesia divergens*
- E) *Borrelia burgdorferi*



INFECTION DISEASE BOARD REVIEW
THE MOST IMPORTANT CASES IN 2021



PREVIEW QUESTION

5.14 Which of the following is the most likely etiologic agent?

- A) *Anaplasma phagocytophilum*
- B) *Ehrlichia chaffeensis***
- C) *Borrelia hermsii*
- D) *Babesia divergens*
- E) *Borrelia burgdorferi*

55 – Daily Question Preview: Day 5

Moderator: Kieren Marr, MD





PREVIEW QUESTION

5.15 28-year-old female presents with recurrent crampy abdominal pain for several months.

She recently returned to the U.S. after living in Tanzania for two years.

Colonoscopy reveals small white papules.

Biopsy of a papule reveals an egg with surrounding granulomatous inflammation.





PREVIEW QUESTION

5.15 Most likely diagnosis?

- A) *Entamoeba histolytica*
- B) *Strongyloides stercoralis*
- C) *Wuchereria bancrofti*
- D) *Schistosoma mansoni*
- E) *Paragonimus westermani*

55 – Daily Question Preview: Day 5



Moderator: Kieren Marr, MD



PREVIEW QUESTION

5.15 Most likely diagnosis?

- A) *Entamoeba histolytica*
- B) *Strongyloides stercoralis*
- C) *Wuchereria bancrofti*
- D) *Schistosoma mansoni***
- E) *Paragonimus westermani*



PREVIEW QUESTION


5.16

A 6-year-old boy from Indiana who has a pet dog and likes to play in a sandbox presents with fever, hepatosplenomegaly, wheezing, and eosinophilia.

He has never travelled outside the continental U.S.

55 – Daily Question Preview: Day 5

Moderator: Kieren Marr, MD




INFECTION DISEASE BOARD REVIEW
THE MOST LIKELY AGENT
Q5 2021

PREVIEW QUESTION

5.16 The most likely causative agent acquired in the sandbox is:

- A) *Anisakis simplex*
- B) *Onchocerca volvulus*
- C) *Enterobius vermicularis*
- D) *Toxocara canis*
- E) *Ancylostoma braziliense*



INFECTION DISEASE BOARD REVIEW
THE MOST LIKELY AGENT
Q5 2021

PREVIEW QUESTION

5.16 The most likely causative agent acquired in the sandbox is:

- A) *Anisakis simplex*
- B) *Onchocerca volvulus*
- C) *Enterobius vermicularis*
- D) *Toxocara canis***
- E) *Ancylostoma braziliense*

55 – Daily Question Preview: Day 5

Moderator: Kieren Marr, MD

INFECTIOUS DISEASE BOARD REVIEW
THE NEXT BEST CASE
Q5 2021

PREVIEW QUESTION

5.17 A 56-year-old man from southern Missouri


Onset in July:

- Myalgia and malaise
- Rash of two days duration
- Tick bite 1 week ago

Exam: T 37.0°C

Annular “bulls-eye” ~6 cm

(same area that engorged tick was removed earlier in the week)



INFECTIOUS DISEASE BOARD REVIEW
THE NEXT BEST CASE
Q5 2021


PREVIEW QUESTION

5.17 Which of the following is the most likely diagnosis?

- A) Lyme disease (*Borrelia burgdorferi* infection)
- B) Human Monocytic Ehrlichiosis (*Ehrlichia chaffeensis*)
- C) *Borrelia mayonii*
- D) Southern tick-associated rash illness (STARI)
- E) *B. lonestarii* infection

55 – Daily Question Preview: Day 5

Moderator: Kieren Marr, MD




**INFECTIOUS
DISEASE**
BOARD REVIEW
THE GREAT NORTH-SIDE
DEB 2021

PREVIEW QUESTION

5.17 Which of the following is the most likely diagnosis?

- A) Lyme disease (*Borrelia burgdorferi* infection)
- B) Human Monocytic Ehrlichiosis (*Ehrlichia chaffeensis*)
- C) *Borrelia mayonii*
- D) Southern tick-associated rash illness (STARI)**
- E) *B. lonestarii* infection

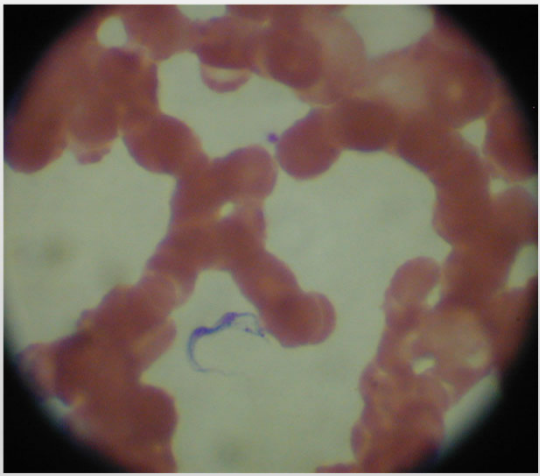


**INFECTIOUS
DISEASE**
BOARD REVIEW
THE GREAT NORTH-SIDE
DEB 2021

PREVIEW QUESTION


5.18 A 41-year-old woman presented to a local emergency department with a one day history of fever associated with swelling and redness in her groin four days after returning from safari in Tanzania.

Peripheral blood smear is obtained.



55 – Daily Question Preview: Day 5

Moderator: Kieren Marr, MD




INFECTION DISEASE BOARD REVIEW
TENTH EDITION, CASE
15 2021

PREVIEW QUESTION

5.18 What is the most likely diagnosis?

- A) *Leishmania donovani*
- B) *Plasmodium vivax*
- C) *Trypanosoma brucei*
- D) *Wuchereria bancrofti*
- E) *Leptospira interrogans*



INFECTION DISEASE BOARD REVIEW
TENTH EDITION, CASE
15 2021

PREVIEW QUESTION

5.18 What is the most likely diagnosis?

- A) *Leishmania donovani*
- B) *Plasmodium vivax*
- C) *Trypanosoma brucei***
- D) *Wuchereria bancrofti*
- E) *Leptospira interrogans*