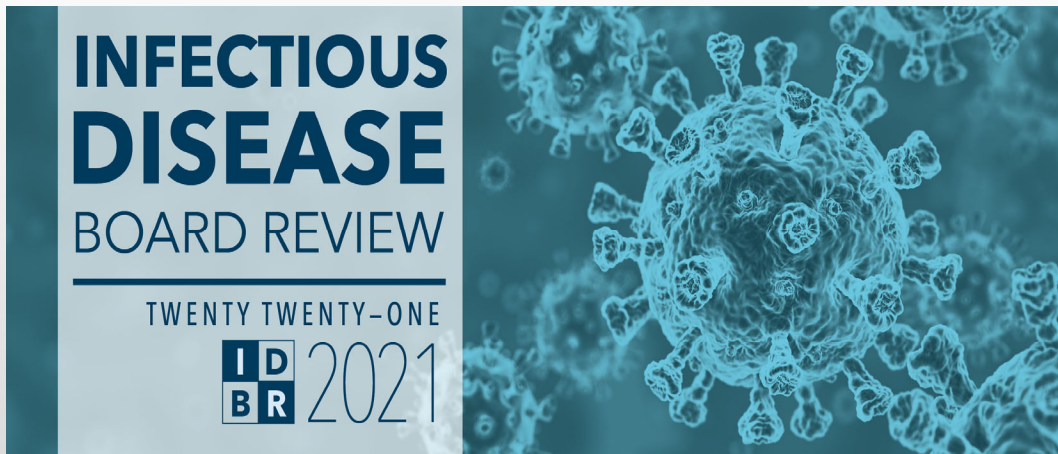

17 – Daily Question Preview: Day 2

Moderator: Andrew Pavia, MD



Daily Question Preview: Day 2

Moderator: Andrew Pavia, MD



2.1 A 32-year-old nurse is 34 weeks pregnant during influenza season.

She develops influenza symptoms and is seen at an instacare where a rapid test is positive and she is given azithromycin.

72 hours after the onset she presents to the ED with fever, tachypnea, hypoxemia and decreased urine output.

CXR shows bilateral hazy infiltrates. She is hospitalized.

17 – Daily Question Preview: Day 2

Moderator: Andrew Pavia, MD

INFECTIOUS
DISEASE
BOARD REVIEW
THE FIRST REVIEW CASE
Qs 2021

PREVIEW QUESTION

2.1 Which of the following is correct?

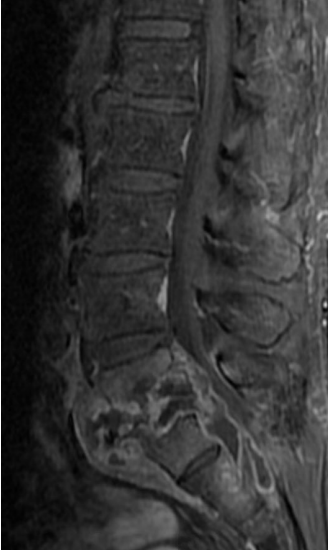
- A) She should get supportive care only since she has had symptoms for >48 hours
- B) Oseltamivir is relatively contraindicated in pregnancy
- C) Zanamivir is clearly preferred because of low systemic absorption
- D) Oseltamivir should be started as soon as possible

INFECTIOUS
DISEASE
BOARD REVIEW
THE FIRST REVIEW CASE
Qs 2021

PREVIEW QUESTION


2.2 57-year-old male presented with 3 months of progressive lower back pain

On ROS denied fevers or chills but wife noticed weight loss
Originally from Cambodia, emigrated as a child
Employed at a seafood processing plant
ESR 84 CRP 16
MRI with discitis and osteomyelitis at L5-S1
Blood cultures grew Staph epidermidis in 2 of 4 bottles



17 – Daily Question Preview: Day 2

Moderator: Andrew Pavia, MD




INFECTIOUS DISEASE
BOARD REVIEW
TENTH EDITION, 2021

PREVIEW QUESTION

2.2 What is the best next step in management?

- A) Repeat 2 sets of blood cultures
- B) Initiate vancomycin; place PICC for six week treatment course
- C) Obtain interferon gamma release assay
- D) Percutaneous biopsy of disc space
- E) Empiric treatment with rifampin, isoniazid, ethambutol, and pyrazinamide



INFECTIOUS DISEASE
BOARD REVIEW
TENTH EDITION, 2021

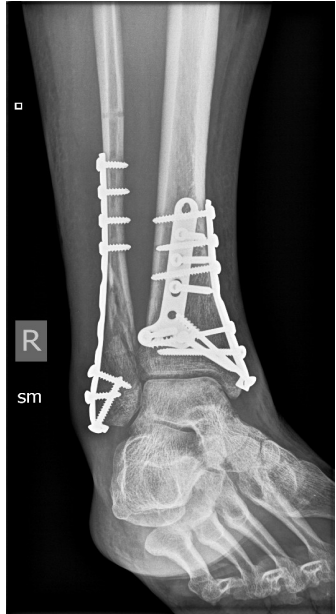
PREVIEW QUESTION

2.3 44-year-old healthy woman suffered a right ankle closed pilon fracture and underwent open reduction and internal fixation (ORIF)

Chronically discharging wound despite courses of cephalexin and trimethoprim-sulfamethoxazole


Two months after ORIF, superficial wound culture grows methicillin-susceptible *Staph aureus*

Plain films: Hardware intact; fracture not yet consolidated



17 – Daily Question Preview: Day 2

Moderator: Andrew Pavia, MD




INFECTIOUS DISEASE BOARD REVIEW
THE NEXT BEST CASE
Q3 2021

PREVIEW QUESTION

2.3 What are your next steps?

- A) Nafcillin followed by long-term trimethoprim- sulfamethoxazole
- B) Hardware removal; six weeks of oxacillin
- C) Hardware removal; six weeks of oxacillin and rifampin
- D) Debridement without hardware removal; six weeks of oxacillin and rifampin
- E) Debridement and hardware replacement; six weeks of oxacillin and rifampin



INFECTIOUS DISEASE BOARD REVIEW
THE NEXT BEST CASE
Q3 2021

PREVIEW QUESTION

2.4 A 63-year-old man with no significant past medical history presents with a week of fever, rigors, and progressive dyspnea on exertion.


Exam : BP 160/40 P110 , 39.5
Rales ½ way up bilaterally
Loud diastolic decrescendo murmur, lower left sternal border

Labs and studies
WBC 23,000 90% PMNS, HCT 30. Platelets 110.
Creatinine 1.6 mg/dl
TTE 1.5 cm oscillating mass, on bicuspid AV with severe aortic regurgitation

3/3 blood cultures: Gram positive cocci in clusters.

17 – Daily Question Preview: Day 2

Moderator: Andrew Pavia, MD




INFECTION DISEASE BOARD REVIEW
PREVIEW QUESTION
ID 2021

2.4

What antibiotic regimen would you recommend pending further information about Gram-positive cocci?

- A) Nafcillin
- B) Vancomycin
- C) Vancomycin + nafcillin
- D) Vancomycin + gentamicin
- E) Vancomycin + gentamicin + rifampin



INFECTION DISEASE BOARD REVIEW
PREVIEW QUESTION
ID 2021

2.5

A 72-year-old man type 2 diabetes mellitus, stage II chronic kidney disease (CKD), and a history of mild aortic stenosis is admitted to the hospital with fever, dysuria, and urinary frequency.

Exam: T38.9oC, Pulse 110 , BP 145/95 mm Hg.
Lungs are clear
3/6 systolic ejection murmur at the right upper sternal boarder.

Lab results
Serum glucose 340 mg/dl
Serum creatinine 1.7 mg/dl, BMP otherwise normal
UA: 3+ protein, 20-50 wbcs/high power field, 4+ glucose.
Two blood cultures and a urine culture are positive for ampicillin-susceptible Enterococcus faecalis.

17 – Daily Question Preview: Day 2

Moderator: Andrew Pavia, MD




INFECTIOUS DISEASE BOARD REVIEW
THE GREAT NORTHWESTERN
HOSPITAL
MAY 2021

PREVIEW QUESTION

2.5 What antibiotic regimen would you recommend for definitive therapy of this patient's infection?

- A) Ampicillin for 2 weeks
- B) Penicillin + gentamicin for 4 weeks
- C) Ampicillin + gentamicin for 4 weeks
- D) Ampicillin + ceftriaxone for 6 weeks
- E) Daptomycin for 8 weeks



INFECTIOUS DISEASE BOARD REVIEW
THE GREAT NORTHWESTERN
HOSPITAL
MAY 2021

PREVIEW QUESTION

2.6 19-year-old woman presented with several days of headache, fever, chills, myalgias, cough & a rash.

On exam she had generalized adenopathy & a vesiculopustular rash with focal areas of hemorrhage progressing in a uniform manner including the entire body, most prominently on the trunk, palms & soles.

She reported her new pet prairie dog was also ill (lethargy, wasting, not eating)

INFECTION DISEASE BOARD REVIEW
THE MOST RELEVANT CASE
DE 2021

PREVIEW QUESTION

2.6



Sejvar JJ, *JID* 2004:190

INFECTION DISEASE BOARD REVIEW
THE MOST RELEVANT CASE
DE 2021


PREVIEW QUESTION

2.6 What is the most likely infection?

- A) *Erysipelothrix rhusiopathiae*
- B) Smallpox
- C) Gambian cutaneous ulcerans
- D) Monkeypox
- E) Yaws (*Treponema pallidum pertenuis*)

17 – Daily Question Preview: Day 2

Moderator: Andrew Pavia, MD




INFECTIOUS DISEASE BOARD REVIEW
TREATY REVIEW CASE
Q5 2021

PREVIEW QUESTION

2.7 25-year-old male presented in July with painful right inguinal mass of one week's duration. He is otherwise well. Married. Monogamous. No hx penile or skin lesion.

Fishing last week in Northern Virginia creek, hiked through wooded area. Picked ticks off legs & neck. Has kitten & dog. Exam: T37oC, 5 cm tender red mass in right midinguinal area, fixed to skin.

Genitalia normal. Aspiration of soft center: 5 cc yellow pus. Gm stain neg. cephalexin 250 mg qid. One week later: mass unchanged. Culture neg. Syphilis FTA & HIV neg.



INFECTIOUS DISEASE BOARD REVIEW
TREATY REVIEW CASE
Q5 2021


PREVIEW QUESTION

2.7 Most likely dx:

- A) *Bartonella henselae*
- B) *Treponema pallidum*
- C) *Haemophilus ducreyi*
- D) *Francisella tularensis*
- E) *Klebsiella (Calymmatobacterium) granulomatis*

17 – Daily Question Preview: Day 2

Moderator: Andrew Pavia, MD



INFECTIOUS DISEASE BOARD REVIEW
TENTH EDITION, 2021

PREVIEW QUESTION

2.8 28-year-old male presents with temp 39°C, diffuse myalgia, headache, malaise. Returned 2 days ago from “Iron Man” race with running, biking, swimming in lake, climbing in Hawaii. Numerous mosquito bites.

Exam: Conjunctival suffusion but no other localizing findings.

WBC 14,500 with 80%PMN, no eos or bands. Platelets 210k.

Bili 2.4, **ALT** 45, **AST** 52, **Alk Phos** 120, **Cr** 1.6. **Hct** 45%. **BC** neg. **UA:** normal



INFECTIOUS DISEASE BOARD REVIEW
TENTH EDITION, 2021


PREVIEW QUESTION

2.8 Most likely diagnosis:

- A) Malaria
- B) Dengue
- C) Ehrlichiosis
- D) Leptospirosis
- E) Zika

17 – Daily Question Preview: Day 2

Moderator: Andrew Pavia, MD




INFECTIOUS DISEASE BOARD REVIEW
THE INFECTION SOCIETY
ID 2021

PREVIEW QUESTION

2.9 67-year-old woman is hospitalized with nosocomial meningitis due to MSSA.

She has a history of allergy to penicillin that is listed in the records as rash; the family recalls that she went to the ED when the rash occurred.

She is not able to corroborate history. She has not received penicillin or cephalosporin antibiotics since the rash occurred a few years ago. Two of her daughters have allergies to penicillin.




INFECTIOUS DISEASE BOARD REVIEW
THE INFECTION SOCIETY
ID 2021

PREVIEW QUESTION

2.9 You are asked about optimal antibiotic treatment. What do you advise?

- A) Administer nafcillin without prior testing
- B) Administer nafcillin after test dose
- C) Skin test for penicillin reaction; if negative then administer nafcillin after test dose
- D) Administer vancomycin
- E) Desensitize to nafcillin




INFECTIOUS DISEASE BOARD REVIEW
THE GREAT NORTHWEST
ID 2021

PREVIEW QUESTION

2.10 A 43-year-old man with diabetes is hospitalized with a closed tibial fracture.

Three years ago when he was being treated for a foot infection with piperacillin-tazobactam he developed a very itchy rash after several weeks of treatment.

The anesthesiologist calls to ask advice about surgical antibiotic prophylaxis prior to operative fixation.



INFECTIOUS DISEASE BOARD REVIEW
THE GREAT NORTHWEST
ID 2021


PREVIEW QUESTION

2.10 What do you do counsel?

- A) Administer clindamycin
- B) Administer cefazolin
- C) Administer cefazolin after intraoperative test dose
- D) Administer ceftriaxone
- E) Administer vancomycin

17 – Daily Question Preview: Day 2

Moderator: Andrew Pavia, MD




INFECTIOUS DISEASE BOARD REVIEW
THE INFECTION SOCIETY OF AMERICA
IS 2021

PREVIEW QUESTION

2.11 45-year-old man, one week of back pain.

He is afebrile and vital signs are normal; normal exam except for tenderness to palpation of the lower back.

MRI shows L3-L4 discitis, hyperemic marrow; 1 of 3 blood cultures is positive for coagulase-negative staphylococci.




INFECTIOUS DISEASE BOARD REVIEW
THE INFECTION SOCIETY OF AMERICA
IS 2021

PREVIEW QUESTION

2.11 Which one of the following would you recommend?

- A) Bone biopsy with culture as the blood isolate is likely a contaminant
- B) Request speciation of the blood isolate
- C) PET-CT to look for another focus of infection for biopsy
- D) Fungal serologies, PPD




INFECTIOUS DISEASE BOARD REVIEW
TENTH EDITION, 2021
10

PREVIEW QUESTION

2.12 On day 9 of nafcillin therapy for complicated methicillin-sensitive *S. aureus* bacteremia the patient has developed new neutropenia (1,000 neutrophils).

MICs ($\mu\text{g/ml}$) of the blood isolate are penicillin 0.12 (S), cefazolin 0.5 (S), vancomycin 1 (S), daptomycin 0.5 (S), ceftaroline 0.5 (S).



INFECTIOUS DISEASE BOARD REVIEW
TENTH EDITION, 2021
10


PREVIEW QUESTION

2.12 Which one of the alternative agents would you recommend?

- A) Penicillin**
- B) Cefazolin**
- C) Vancomycin**
- D) Daptomycin**

17 – Daily Question Preview: Day 2

Moderator: Andrew Pavia, MD




INFECTIOUS DISEASE BOARD REVIEW
THIRTY-NINTH CASE
JULY 2021

PREVIEW QUESTION

2.13 A patient with complicated MRSA bacteremia on day 9 of therapy with daptomycin q48h develops myalgias with a creatinine kinase of 1250 u/L (upper limit of normal 200).

The last positive blood culture was on day 3 of therapy.

MICs ($\mu\text{g/ml}$) of the isolate are as follows: vancomycin 2 (S), daptomycin 0.5 (S), dalbavancin 0.25 (S), telavancin 0.5 (S), ceftaroline 1 (S).




INFECTIOUS DISEASE BOARD REVIEW
THIRTY-NINTH CASE
JULY 2021

PREVIEW QUESTION

2.13 Which one of the following would you recommend?

- A) Ceftaroline
- B) Dalbavancin
- C) Telavancin
- D) Vancomycin
- E) Linezolid




INFECTIOUS DISEASE BOARD REVIEW
TENTH EDITION, 2021

PREVIEW QUESTION

2.14 What is the most likely source for humans to acquire *H. pylori* infection?

- A) Perinatally from mother**
- B) Ingestion of raw vegetables**
- C) Ingestion of undercooked meat**
- D) Ingested tap water from a municipal source**
- E) Contact with infected secretions from another human**



INFECTIOUS DISEASE BOARD REVIEW
TENTH EDITION, 2021



PREVIEW QUESTION

2.15 Which of the following is the most appropriate next step for evaluating a 29-year-old previously healthy but overweight male patient with typical retrosternal heartburn symptoms?

- A) Stool antigen test for *H. pylori***
- B) Urea breath test for *H. pylori***
- C) No testing for *H. pylori***
- D) Serological testing for *H. pylori***
- E) Empiric therapy for *H. pylori* regardless of testing**

17 – Daily Question Preview: Day 2



Moderator: Andrew Pavia, MD



PREVIEW QUESTION

2.16 After treatment of this patient for Hp gastritis, the H. pylori stool antigen test should be repeated:

- A) On the final day of H. pylori therapy
- B) Two weeks after completion of H. pylori therapy
- C) Eight weeks after completion of H. pylori therapy
- D) The test should not be repeated to assess cure



PREVIEW QUESTION

2.17 An asymptomatic patient with a new diagnosis of HIV (CD4 = 10 cells/uL and HIV Viral Load 300,000 copies/uL is started on antiretroviral therapy (dolutegravir plus tenofovir alafenamide/emtricitabine)


His labs are unremarkable as is his chest xray

His serum toxoplasma IgG is positive

He asks whether you want to add prophylaxis for pneumocystis pneumonia but warns you that twice when he has taken sulfonamides he has developed hives and laryngeal edema

17 – Daily Question Preview: Day 2

Moderator: Andrew Pavia, MD




INFECTION DISEASE BOARD REVIEW
THE GREAT NORTHWESTERN
MEDICAL CENTER
JULY 2021

PREVIEW QUESTION

2.17 What would you recommend regarding PCP and Toxo prophylaxis?

- A) No chemoprophylaxis: his viral load should fall quickly, and his CD4 will rise quickly in response to this first exposure to antiretroviral therapy
- B) Trimethoprim sulfamethoxazole plus solu-medrol dose pak
- C) Dapsone
- D) Aerosol pentamidine plus pyrimethamine
- E) Atovaquone



INFECTION DISEASE BOARD REVIEW
THE GREAT NORTHWESTERN
MEDICAL CENTER
JULY 2021

PREVIEW QUESTION

2.18 A 45-year-old woman with HIV (CD4 = 50 cells/uL, HIV viral load = 500,000 copies/uL) presents with fever, shortness of breath, room air P02 =80mm Hg) and diffuse bilateral infiltrates and is started on TMP-SMX.

The bronchoalveolar lavage is positive for pneumocystis by direct fluorescent antibody test.

The cytology lab reports several CMV inclusion bodies in the BAL.

17 – Daily Question Preview: Day 2

Moderator: Andrew Pavia, MD

INFECTIOUS
DISEASE
BOARD REVIEW
THIRTY-NINTH EDITION
2021

PREVIEW QUESTION

2.18 The best course of action in addition to considering antiretroviral therapy would be:

- A) To add ganciclovir to the TMP-SMX regimen
- B) To add prednisone to the TMP-SMX regimen
- C) To add ganciclovir plus prednisone to the TMP-SMX regimen
- D) To add ganciclovir plus IVIG to the regimen
- E) To add nothing, ie continue TMP-SMX alone