



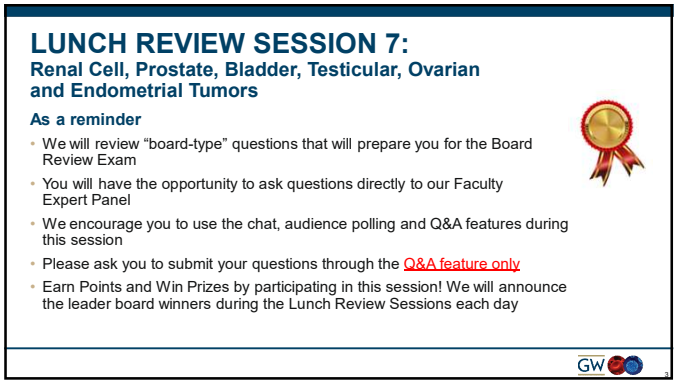

© 2021 Hematology and Oncology Best Practices Course

Using the Polling and Q&A features

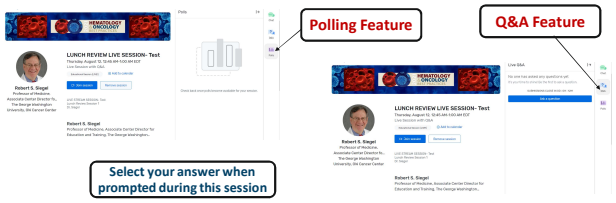

MOCK QUESTIONS: LET'S PRACTICE!

MOCK QUESTION

What is your attendee type for this conference?

A. Physician
B. Medical Fellow | Resident
C. Nurse or Nurse Practitioner
D. Pharmacist
E. Other Healthcare Provider
F. Industry Life Sciences Representative

© 2021 Hematology and Oncology Best Practices Course

MOCK QUESTION

What is your preferred "grab n' go" lunch?

A. Pizza
B. Burger & Fries
C. Greens Salad
D. Soup & Sandwich
E. Sushi
F. Other

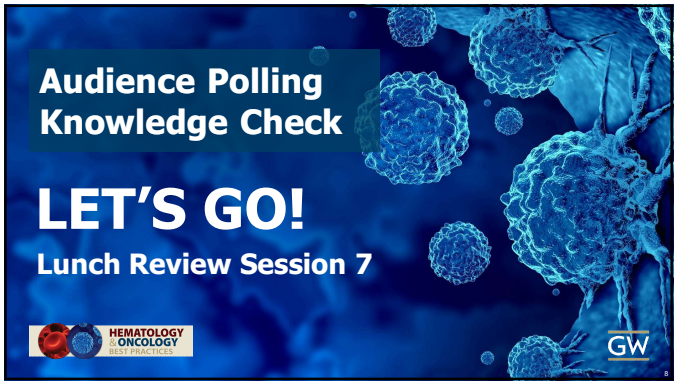

1. Prostate Cancer
(Aragon-Ching)

A 61 y/o male presents with a history of high-risk prostate cancer, 5 out of 12 cores positive for Gleason 4+5=9 and underwent surgery with radical prostatectomy. Final pathology showed Gleason 5+4=9, with seminal vesicle invasion and extra-prostatic extension (pT3bN0Mx) prostate cancer, with 0 out of 8 lymph nodes involved. His CT scan and bone scan obtained after surgery was negative for any evidence of metastases. His PSA checked at 3 months after surgery was undetectable at < 0.1 ng/ml. He has felt well after surgery with no urinary or continence issues. However, 12 months after surgery, he underwent PSA testing that showed detectable PSA at 0.2 ng/ml confirmed 2 months later. He had re-staging CT and technetium bone scans that did not show obvious distant sites of metastasis and no obvious local recurrence in the prostate bed. He comes in for consultation regarding the next treatment option.

© 2021 Hematology and Oncology Best Practices Course

1. Prostate Cancer
(Aragon-Ching)

You discuss the following options:

A. Offer salvage radiation + ADT
B. Offer ADT + apalutamide
C. Offer ADT + darolutamide
D. Offer ADT + enzalutamide + docetaxel
E. Offer ADT + enzalutamide

[1]Thompson et al. J Urol. 2009: 956; [2]Bolla et al. Lancet. 2005: 572; [3]Wiegel et al. JCO 2009.: 2924; [4]Freedland et al. JCO 2014: 8525 ; Sachdev S et al., JAMA Oncol . 2020 Nov 1;6(11):1793-1800; Vale C et al., Lancet. 2020 Oct 31;396(10260):1422-1431; Parker C et al., Lancet.2020; Sargos P et al., Lancet Oncol . 2020 Oct;21(10):1341-1352; Kneebone A et al., Lancet Oncol . 2020 Oct;21(10):1331-1340; Pisansky et al., J Urol. 2019 Sep;202(3):533-538

10

2. Prostate Cancer
(Aragon-Ching)

A 57 y/o male presented to the hospital for increasing back pain that has occurred over the past few months. An imaging done with MRI at the ER showed multiple (>10) osseous lesions in both the axial and appendicular skeleton and several bulky adenopathy. Further staging scans with bone scan and CT scan showed multiple bone metastases in the ribs, spine/axial and appendicular skeleton and an enlarged prostate which was later confirmed to be prostate cancer on biopsy which revealed Gleason 5+4=9 prostate adenocarcinoma with an elevated PSA of 2,000 ng/ml. His back pain responded to intake of ibuprofen and now has improved pain. Performance status is ECOG 0.

What would be your next recommended step?

A. Start cabazitaxel, he was symptomatic on presentation
B. Start Sipuleucel-T, he is now asymptomatic after NSAID use
C. Start androgen deprivation therapy (either degarelix or bicalutamide then leuprolide) followed by 6 cycles of docetaxel
D. Start ADT and docetaxel and abiraterone and enzalutamide

11

3. Renal Cell Carcinoma
(Bajorin)

A patient presenting with benign hair follicle tumors (fibrofolliculomas), pulmonary cysts with a history of pneumothorax in the past, and bilateral renal tumors has which of the following syndromes?

A. Hereditary Papillary Renal Cell Carcinoma
B. Hereditary Leiomyomatosis Renal Cell Carcinoma (HLRCC)
C. Birt-Hogg-Dubé Syndrome
D. None of the above

12

© 2021 Hematology and Oncology Best Practices Course

4. Renal Cell Carcinoma
(Bajorin)

Von Hippel-Landau disease has the following association with renal cell carcinoma (RCC):

A. It is an autosomal dominant syndrome in which 90% of affected individuals develop RCC.
B. Up to 45% of affected individuals develop RCC at a median age of 39 years.
C. Bilateral renal tumors develop at a young age requiring bilateral nephrectomy in the majority of patients.
D. Affected individuals' VHL gene functions as a tumor suppressor gene resulting in a high incidence of astrocytomas and retinoblastoma as well as RCC.

13

5. Prostate Cancer
(Aragon-Ching)

A 61 y/o otherwise healthy Caucasian male comes to you for an opinion regarding treatment for a recently diagnosed prostate adenocarcinoma. He had a Gleason 3+3=6 prostate cancer, clinical T1c with PSA of 4.6 ng/ml.

Which of the following would not be a reasonable option regarding treatment approach for low-risk prostate cancer?

A. Brachytherapy
B. EBRT
C. Active surveillance
D. 3 months of ADT + enzalutamide and abiraterone followed by RP
E. Radical prostatectomy

14

6. Bladder Cancer
(Bajorin)

A 58 year-old male patient has a history of transitional cell carcinoma of the bladder initially treated with cystoprostatectomy and bilateral pelvic lymph node dissection. Two years later he develops metastatic disease in the para-aortic lymph nodes confirmed by fine needle aspiration. The remainder of the evaluation shows no other site of metastases. He has an excellent performance status, normal renal function, no medical co-morbidities, and a positive PD-L1 stain of his tumor.

Approved therapies include:

A. Carboplatin-based chemotherapy dosing by AUC plus neither either gemcitabine or paclitaxel.
B. Combination chemotherapy with atezolizumab plus either carboplatin-gemcitabine or cisplatin-gemcitabine.
C. Cisplatin based-chemotherapy, with either MVAC or cisplatin-gemcitabine.
D. Retroperitoneal lymph node dissection.
E. A and C

15

© 2021 Hematology and Oncology Best Practices Course

7. Prostate Cancer
(Aragon-Ching)

A 69 year-old male presents with prostate cancer that was previously treated with prostatectomy 5 years ago. He had Gleason 5+4=9 pT3N0 prostate adenocarcinoma and did not undergo any adjuvant therapy. His PSA was initially undetectable but after 2 years, started having rising PSA and when it rose to a PSA of 5 ng/ml, he was started on Leuprolide. However, his PSA started rising from 0.5 ng/ml to 1 ng/ml in 3 months and to 4.5 ng/ml in another 3 months with testosterone of < 10 ng/dl. A CT scan and bone scan obtained was negative for metastatic disease. Your patient asks about additional treatment that could delay metastases or improve survival.

7. Prostate Cancer
(Aragon-Ching)

You discuss the following:

A. Apalutamide has been FDA approved for treatment of non-metastatic CRPC
B. Darolutamide has been shown to improve metastasis-free survival
C. Enzalutamide has been shown to improve metastasis-free survival
D. Apalutamide, darolutamide and enzalutamide have been shown to improve overall survival
E. All of the above

8. Renal Cell Carcinoma
(Bajorin)

The following treatments have shown clinical benefit as 1st line treatment for patients with metastatic RCC:

A. nivolumab and ipilumimab
B. axitinib plus pembrolizumab
C. cabozantinib plus nivolumab
D. Lenvatinib plus pembrolizumab
E. All of the above

© 2021 Hematology and Oncology Best Practices Course

9. Renal Cell Carcinoma
(Bajorin)

Randomized trial results assessing peri-operative therapy for patients undergoing nephrectomy for renal cell carcinoma demonstrate:

A. A survival benefit for patients treated with adjuvant sunitinib
B. Benefit from adjuvant vaccine immunotherapy
C. Enhanced survival for patients treated with adjuvant pembrolizumab
D. Improved survival for patients treated with adjuvant high-dose interleukin-2
E. A and C

Lastname, et al. *Journal Name Abbreviated*. 2004;100:1234-1235.

19

10. Endometrial Cancer
(Wahner-Hendrickson)

A 68 year old woman presents with recurrent pMMR, HER2+ high grade serous endometrial cancer. She completed her adjuvant therapy, which consisted of pelvic radiation and carboplatin/paclitaxel approximately 5 months ago.

Which of the following regimens would you recommend to best improve her PFS?

A. Carboplatin, paclitaxel and trastuzumab
B. Weekly paclitaxel
C. Doxorubicin
D. Pembrolizumab
E. Pembrolizumab and lenvatinib

20

11. Endometrial Cancer
(Wahner-Hendrickson)

68 year old undergoes surgical staging for a new diagnosis of endometrial cancer. Imaging does not show any metastatic disease. She undergoes surgical staging and final pathology is consistent a 2 cm grade 1 endometrioid adenocarcinoma invading 3m into a 20 mm myometrium. There was no lymphovascular space invasion, no cervical involvement and lymph nodes are negative.

You recommend which of the following?

A. Surveillance
B. Adjuvant chemotherapy with carboplatin/paclitaxel
C. Adjuvant pelvic radiation
D. Combination of chemotherapy and radiation
E. Adjuvant letrozole therapy

21

© 2021 Hematology and Oncology Best Practices Course

12. Prostate Cancer
(Aragon-Ching)

A 73 y/o male was diagnosed initially with metastatic prostate cancer to lymph nodes and bone after biopsy of the bone and prostate tumor biopsy consistent with prostate adenocarcinoma Gleason 4+5=9. He was treated with androgen deprivation therapy (ADT) and abiraterone with prednisone with PSA response from 200 ng/ml to 4 ng/ml after 1 year. However, PSA started rising to 12 ng/ml in 1 month and re-staging CT and bones scan showed radiographic progression. He had initial Invitae germline testing showing BRCA2 mutation and genomic sequencing of the prostate was also consistent with BRCA2 mutation. What would be the next FDA-approved treatment option?

22

12. Prostate Cancer
(Aragon-Ching)

What would be the next FDA-approved treatment option?

A. Olaparib
B. Talazoparib
C. Rucaparib
D. Niraparib
E. Lutetium

23

13. Bladder Cancer
(Bajorin)

A 56 year-old male patient with transitional cell carcinoma presents with carcinoma in-situ involving the trigone of the bladder. The patient is treated with BCG therapy without response. He is then treated with intravesical BCG plus interferon but again no response is seen. Repeat transurethral resection shows persistent carcinoma-in-situ along with new tumor invading the lamina propria but not the muscularis propria.

Therapeutic options include:

A. Radical cystectomy with preservation of the prostate and neurovascular bundle to preserve sexual function
B. Cystoprostatectomy and bilateral pelvic lymph node dissection
C. Intravesical gemcitabine
D. Pembrolizumab
E. B and D

24

© 2021 Hematology and Oncology Best Practices Course

14. Bladder Cancer
(Bajorin)

Maintenance therapy starting immediately after completion of chemotherapy in patients with metastatic disease is FDA approved for:

A. Pemetrexed
B. Atezolizumab
C. Avelumab
D. Pembrolizumab
E. A and C
F. B and D

15. Testicular Cancer
(Feldman)

A 25-year-old man is status post left orchiectomy 2 weeks ago for a 5cm, pT2 mixed nonseminoma (40% embryonal carcinoma, 40% teratoma, 20% yolk sac tumor). CT scan reveals a 3cm left paraaortic lymph node and several lung metastases. Preoperative tumor markers were AFP 1500ng/mL, HCG 508 mIU/mL, and LDH 245 U/L (reference range 100 to 250U/L). Today's labs demonstrate AFP 769ng/mL, HCG 840mIU/mL, and LDH 252U/L.

Which of the following is the most appropriate treatment plan?

A. Bleomycin, Etoposide, and Cisplatin for 4 cycles (BEPx4)
B. Etoposide and Cisplatin for 4 cycles (EPx4)
C. Etoposide, Ifosfamide, and Cisplatin for 3 cycles (VIPx3)
D. Etoposide and Cisplatin for 3 cycles (EPx3)
E. Bleomycin, Etoposide, and Cisplatin x 2 cycles (BEPx2)

16. Ovarian Cancer
(Wahner-Hendrickson)

72-year-old woman presented with increasing abdominal discomfort and bloating. Her past medical history is significant for stage III ovarian cancer. She underwent an optimal surgical debulking and adjuvant chemotherapy with carboplatin and paclitaxel. She completed her chemotherapy 18 months ago and had no evidence of disease at the end of her treatment. Imaging reveals significant ascites as well as diffuse peritoneal carcinomatosis.

You recommend which of the following:

A. Secondary surgical debulking followed by platinum containing therap
B. Carboplatin, gemcitabine and bevacizumab therapy
C. Weekly paclitaxel and bevacizumab
D. Olaparib

© 2021 Hematology and Oncology Best Practices Course

17. Ovarian Cancer
(Wahner-Hendrickson)

A 63-year-old woman presents following an optimal surgical debulking for stage IIIC high-grade serous ovarian cancer. She was seen by a genetic counselor and was found to have a germline BRCA1 mutation.

You recommend which of the following?

A. Carboplatin/paclitaxel followed by bevacizumab maintenance therapy
B. Carboplatin/paclitaxel followed by olaparib maintenance therapy
C. Carboplatin/paclitaxel/niraparib followed by niraparib maintenance therapy
D. Olaparib monotherapy

28

18. Bladder Cancer
(Bajorin)

FDA approval supports both 1st and 2nd-line treatment of urothelial cancer with:

A. Paclitaxel
B. Atezolizumab
C. Pembrolizumab
D. Nivolumab
E. B and C

29

19. Ovarian Cancer
(Wahner-Hendrickson)

A 73-year-old female presents with increasing abdominal bloating and early satiety. She completed her initial therapy for Stage IIIC ovarian cancer 10 months ago. She had undergone an optimal debulking and completed 6 cycles of carboplatin and paclitaxel followed by olaparib maintenance therapy as she was found to have a BRCA mutation. Imaging reveals diffuse peritoneal carcinomatosis and ascites.

You recommend which of the following?

A. Niraparib
B. Gemcitabine and bevacizumab
C. Secondary surgical debulking
D. Carboplatin, gemcitabine and bevacizumab

30

© 2021 Hematology and Oncology Best Practices Course

20. Endometrial Cancer
(Wahner-Hendrickson)

A 54 year old woman presents to medical oncology after undergoing a staging procedure for a new diagnosis of high grade serous endometrial cancer with metastases to the omentum. Pathology report notes microsatellite instability and IHC for MSH6 is absent.

In addition to discussing adjuvant therapy, what additional testing would you recommend?

A. Genetic counseling and testing for Lynch syndrome related germline mutations
B. HER2 testing
C. IHC for estrogen and progesterone receptors
D. A and B
E. A and C

31

21. Renal Cell Carcinoma
(Bajorin)

Histologic classification of malignant renal cell tumors includes the following basic cell types:

A. Adenocarcinoma, sarcomatoid and oncocytoma
B. Clear cell, chromaphobe and unclassified.
C. Cystic, solid and mixed.
D. Papillary, collecting duct and neuroendocrine
E. Both B and D

32

22. Bladder Cancer
(Bajorin)

Conventional surgical recommendation(s) for a female patient with muscle-invasive, high-grade transitional cell carcinoma of the bladder include:

A. Cystectomy for trigone tumors and partial cystectomy for lateral tumors
B. Cystectomy and unilateral pelvic lymph node dissection based on tumor size and location
C. Cystectomy and bilateral pelvic lymph node dissection
D. Cystectomy, total abdominal hysterectomy, bilateral salpingo-oophorectomy, resection of part of the vaginal vault and bilateral pelvic lymph node dissection.
E. None of the above

33

© 2021 Hematology and Oncology Best Practices Course

23. Ovarian Cancer
(Wahner-Hendrickson)

A 65 year old female was treated with carboplatin and paclitaxel for 6 cycles after an optimal debulking surgery for her Stage IIIC high grade serous ovarian cancer. Tumor testing reveals a positive HRD score. Imaging reveals a complete response after completion of chemotherapy.

You recommend which of the following to best improve her PFS?

A. Observation
B. Maintenance bevacizumab
C. Maintenance niraparib
D. Maintenance bevacizumab and olaparib
E. Maintenance paclitaxel therapy

24. Ovarian Cancer
(Wahner-Hendrickson)

A 25 year old woman presents with an 8 cm solid mass in her left ovary. Additional CT imaging does not reveal any other areas of concern. She undergoes a left salpingo oophorectomy which included peritoneal washing and careful inspection. Pathology is consistent with a grade 1 immature teratoma. You see her talk to her about adjuvant therapy.

You recommend which of the following?

A. Observation
B. External pelvic radiation
C. Three cycles of BEP (bleomycin,etoposide,cisplatin)
D. Four cycles of BEP
E. Three cycles carboplatin and paclitaxel

25. Testicular Cancer
(Feldman)

A 51-year-old man self palpates a right testicular mass confirmed to be suspicious on ultrasound. CT of the chest, abdomen, and pelvis demonstrates a 1.6c interaortocaval lymph node. Serum tumor markers are normal. Which of the following is the most appropriate next diagnostic test?

Which of the following is the most appropriate next diagnostic test?

A. Ultrasound-guided biopsy of the right testicular mass
B. Right radical inguinal orchiectomy
C. CT-guided retroperitoneal lymph node biopsy
D. FDG-PET scan
E. Bone marrow aspirate and biopsy

© 2021 Hematology and Oncology Best Practices Course

26. Ovarian Cancer
(Wahner-Hendrickson)

An 81 year old woman presents to medical oncology after undergoing a suboptimal debulking procedure for her recent diagnosis of Stage IV high grade serous ovarian cancer. Somatic testing reveals that her tumor is HR proficient (HRD negative).

You recommend which of the follow adjuvant therapy options?

A. 6 cycles of IV/IP carboplatin and paclitaxel
B. 6 cycles of carboplatin, paclitaxel and bevacizumab followed by bevacizumab maintenance therapy
C. 6 cycles of carboplatin, paclitaxel and bevacizumab followed by bevacizumab and olaparib maintenance therapy
D. 6 cycles of carboplatin, paclitaxel and bevacizumab followed by olaparib maintenance therapy
E. 6 cycles of IV/IP cisplatin and paclitaxel

37

THANK YOU

38

© 2021 Hematology and Oncology Best Practices Course